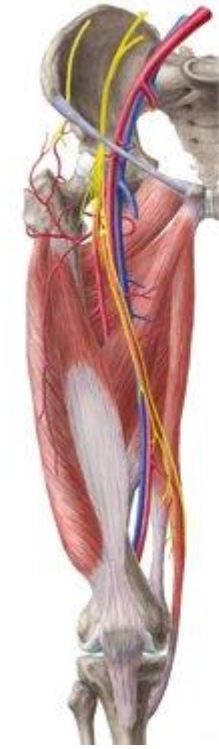




# Anatomía Extremidad Inferior Parte II

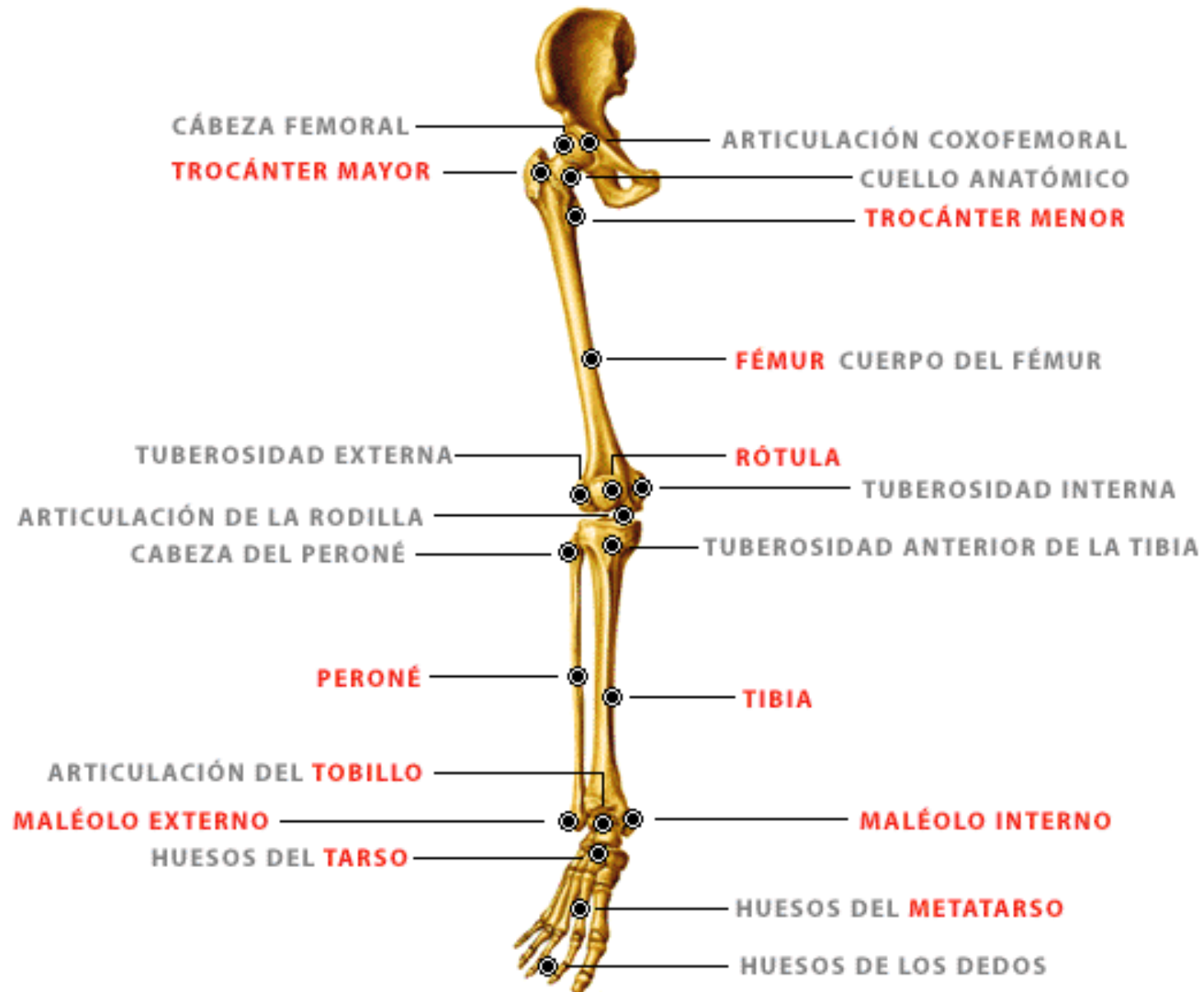
---



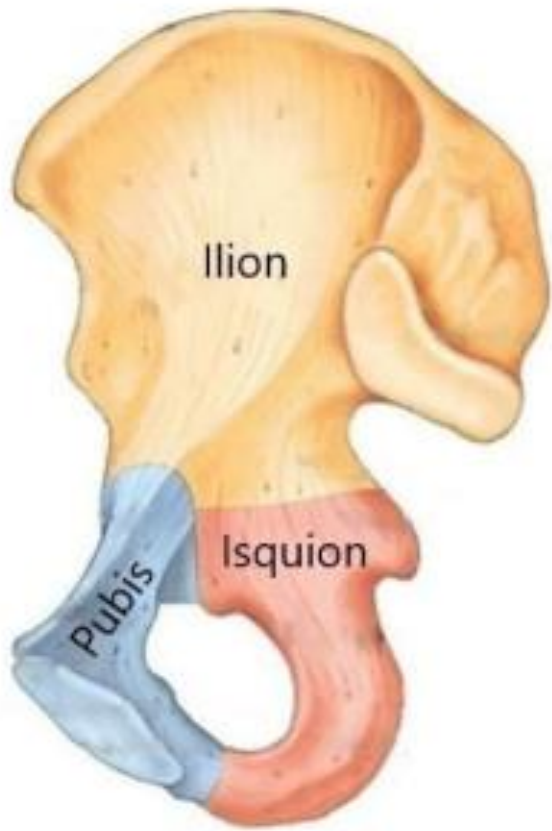
EDUARDO SOTO B.

EDUARDOSOTOKINE@GMAIL.COM

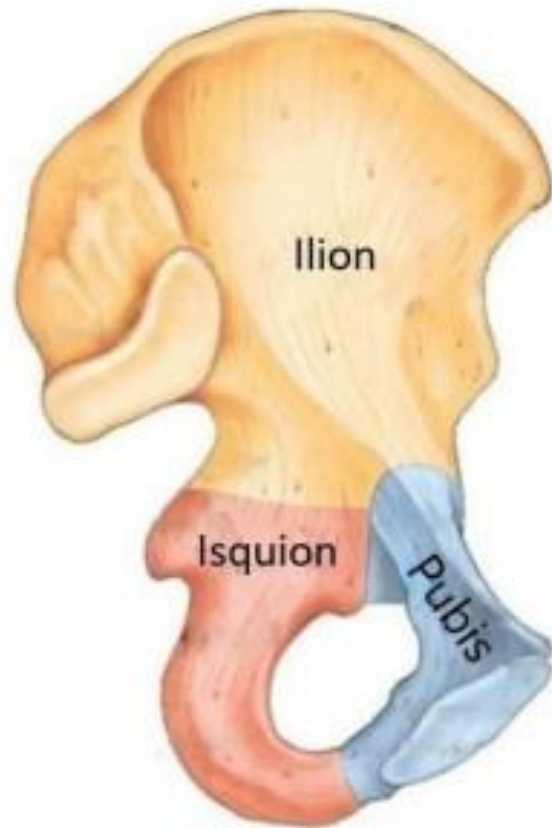
# Extremidad Inferior



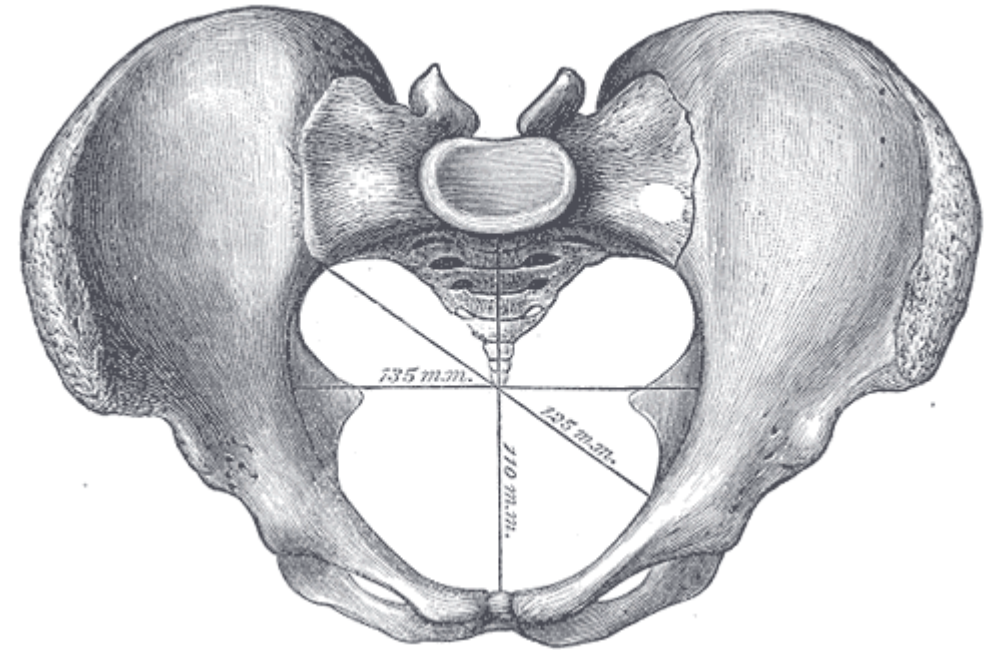
# Hueso coxal



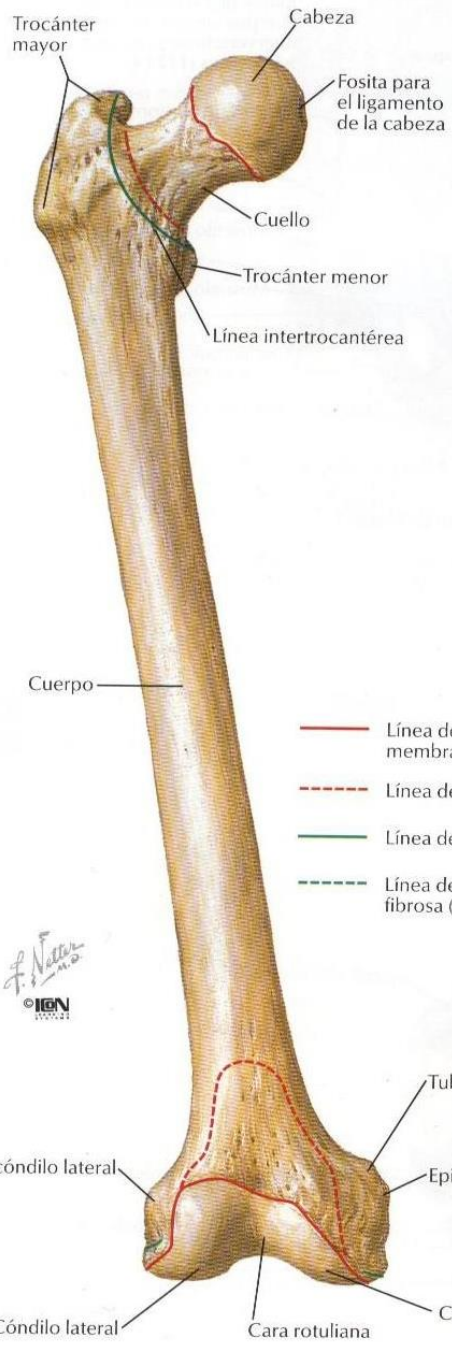Coxal derecho



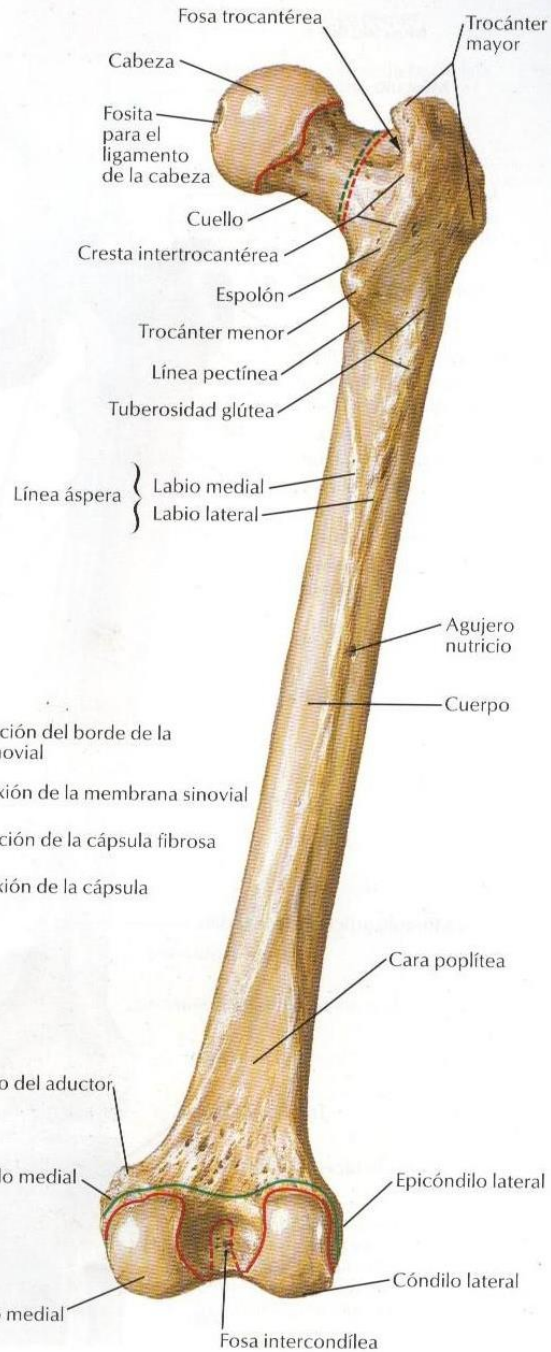
Coxal izquierdo



### Visión anterior

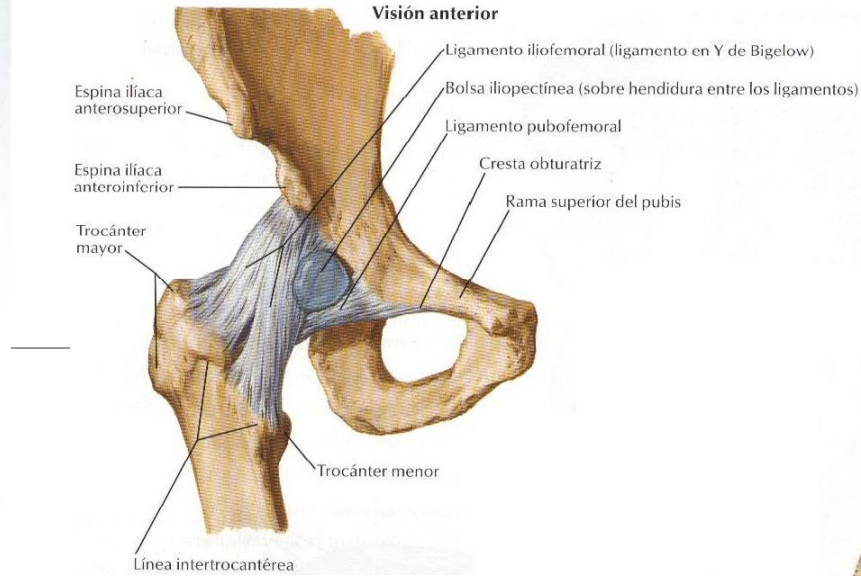


### Visión posterior

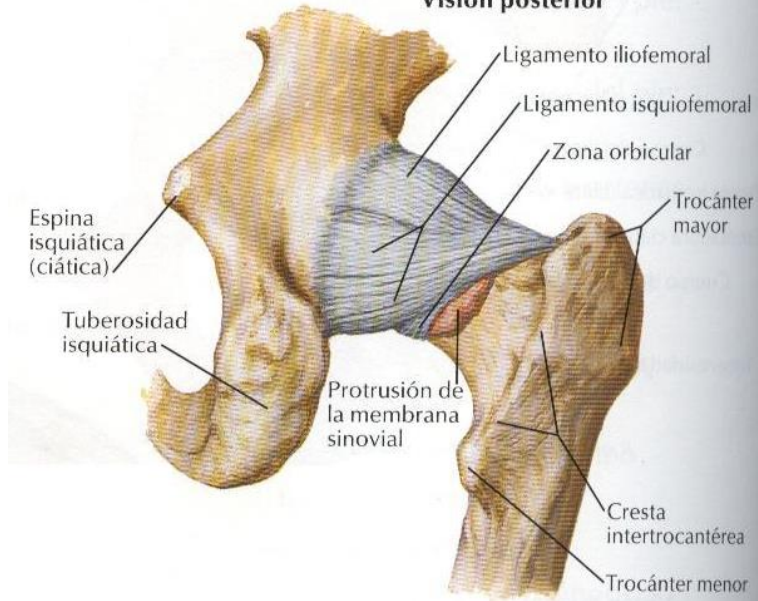


- Línea de inserción del borde de la membrana sinovial
- - - Línea de reflexión de la membrana sinovial
- Línea de inserción de la cápsula fibrosa
- - - Línea de reflexión de la cápsula fibrosa (libre)

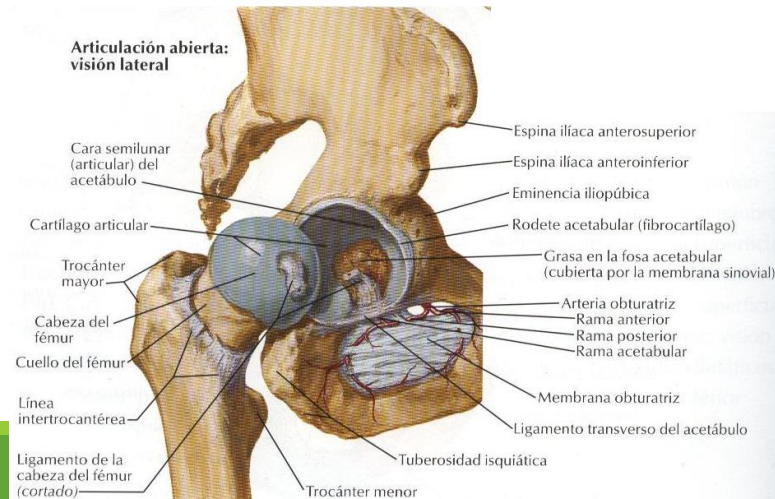
### Visión anterior



### Visión posterior

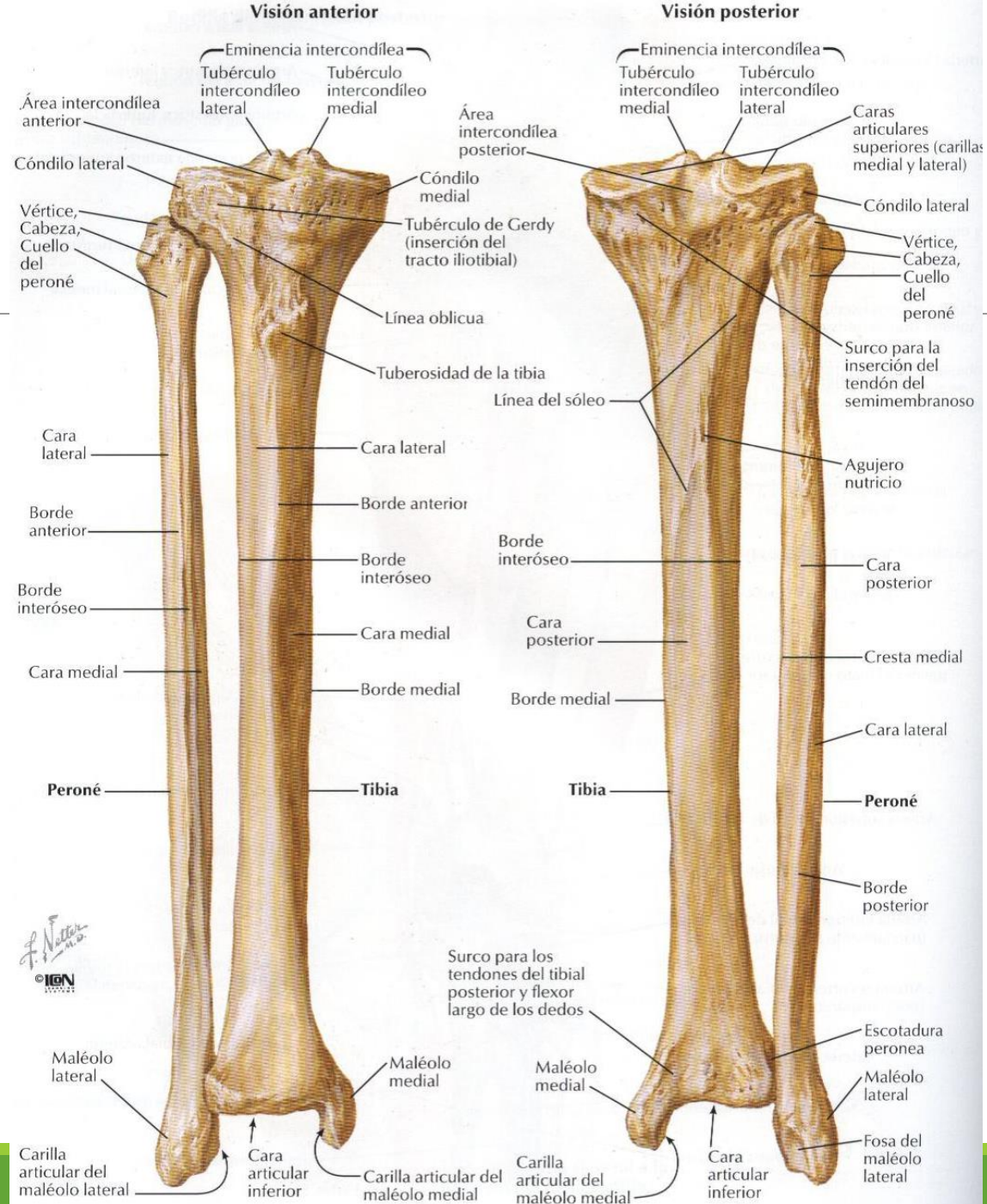


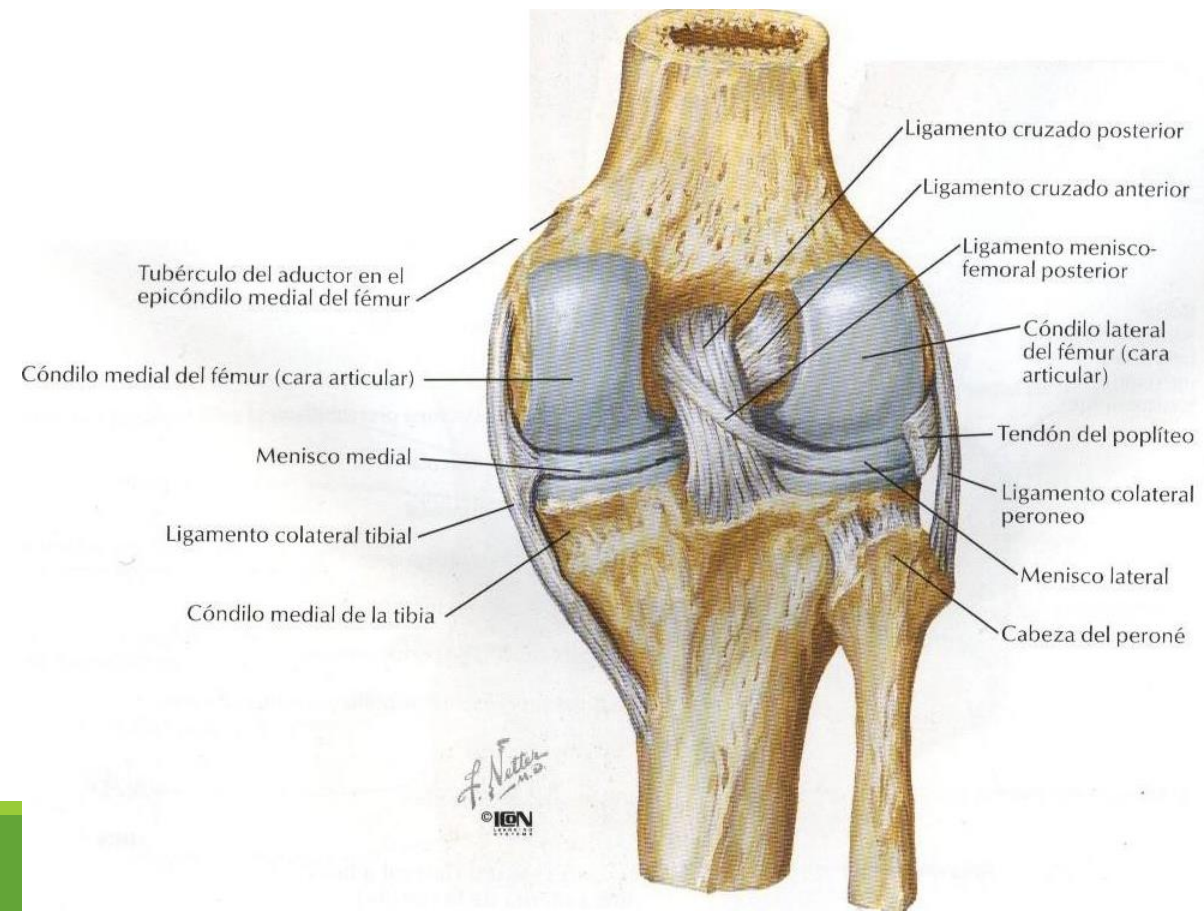
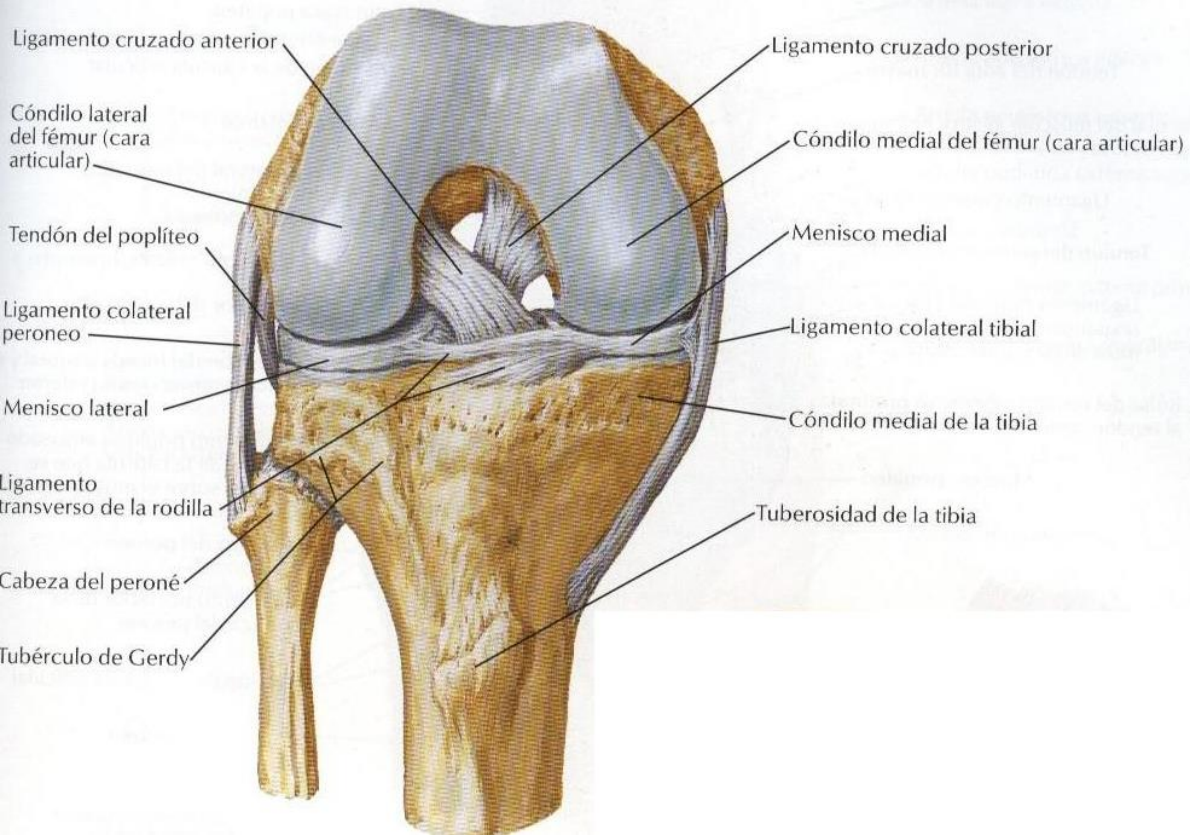
### Articulación abierta: visión lateral



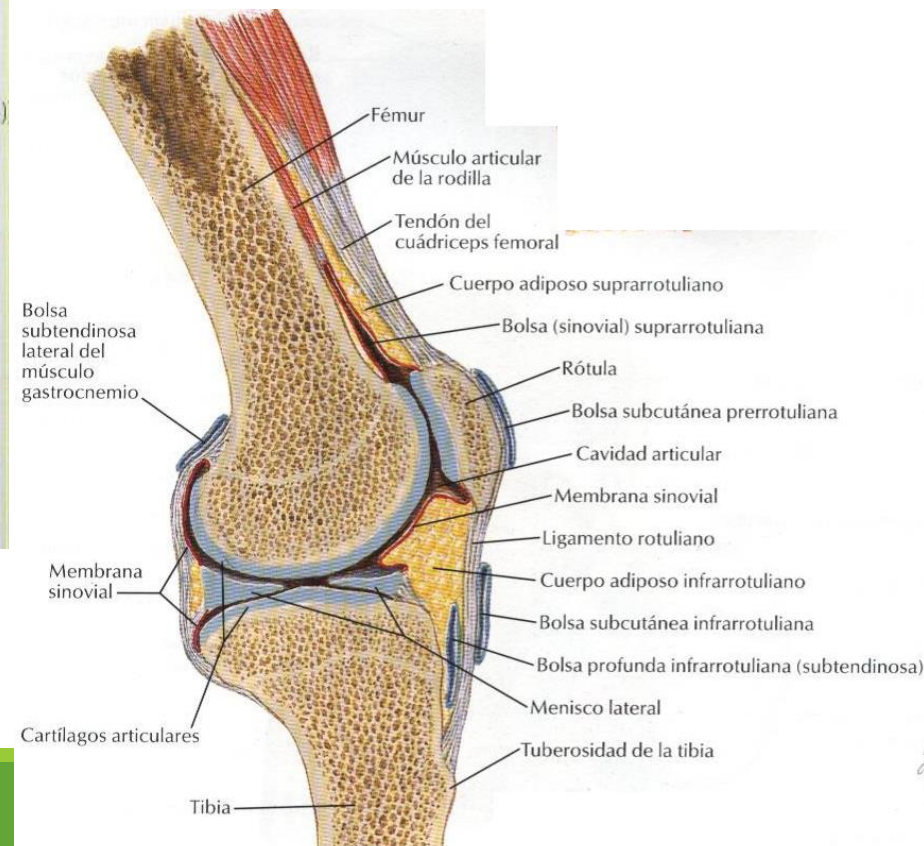
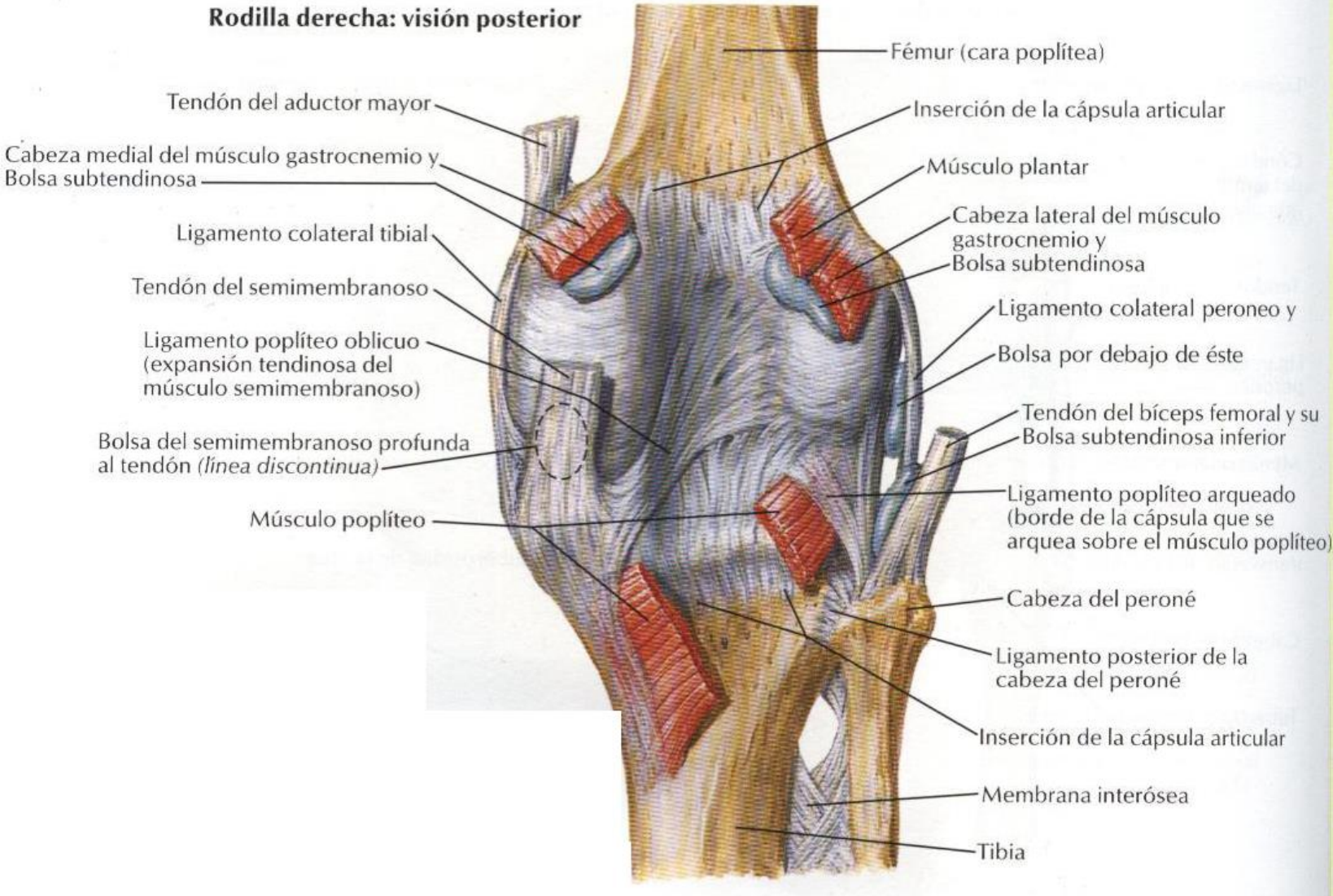
F. Netter M.D.  
© IGEN

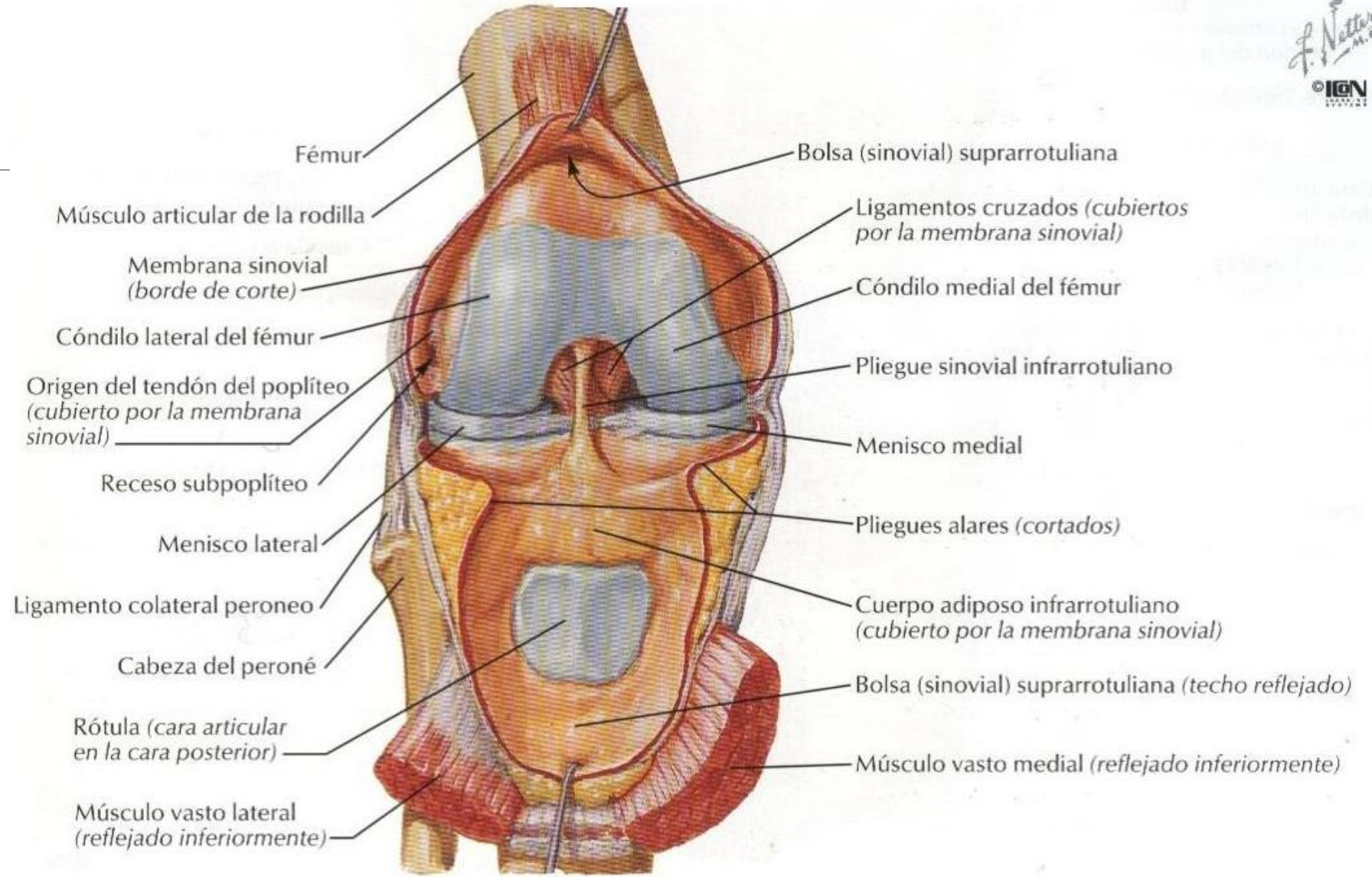
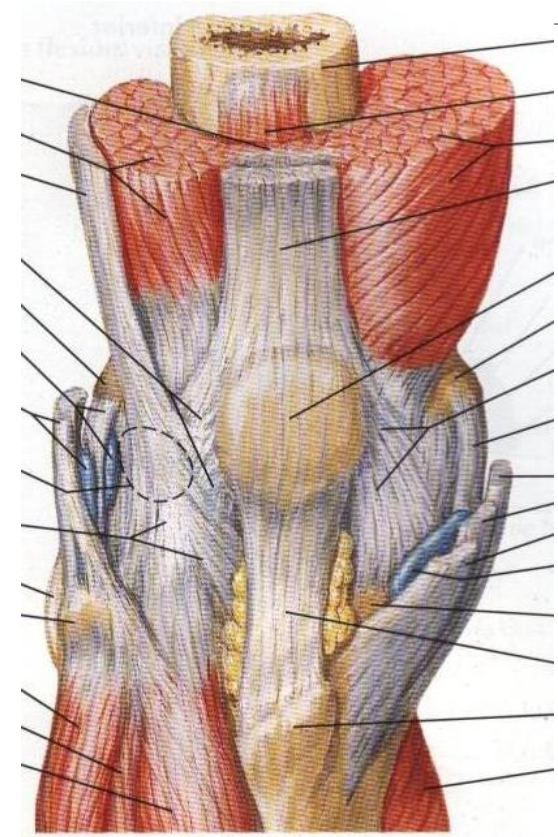
# Tibia y peroné (fíbula)



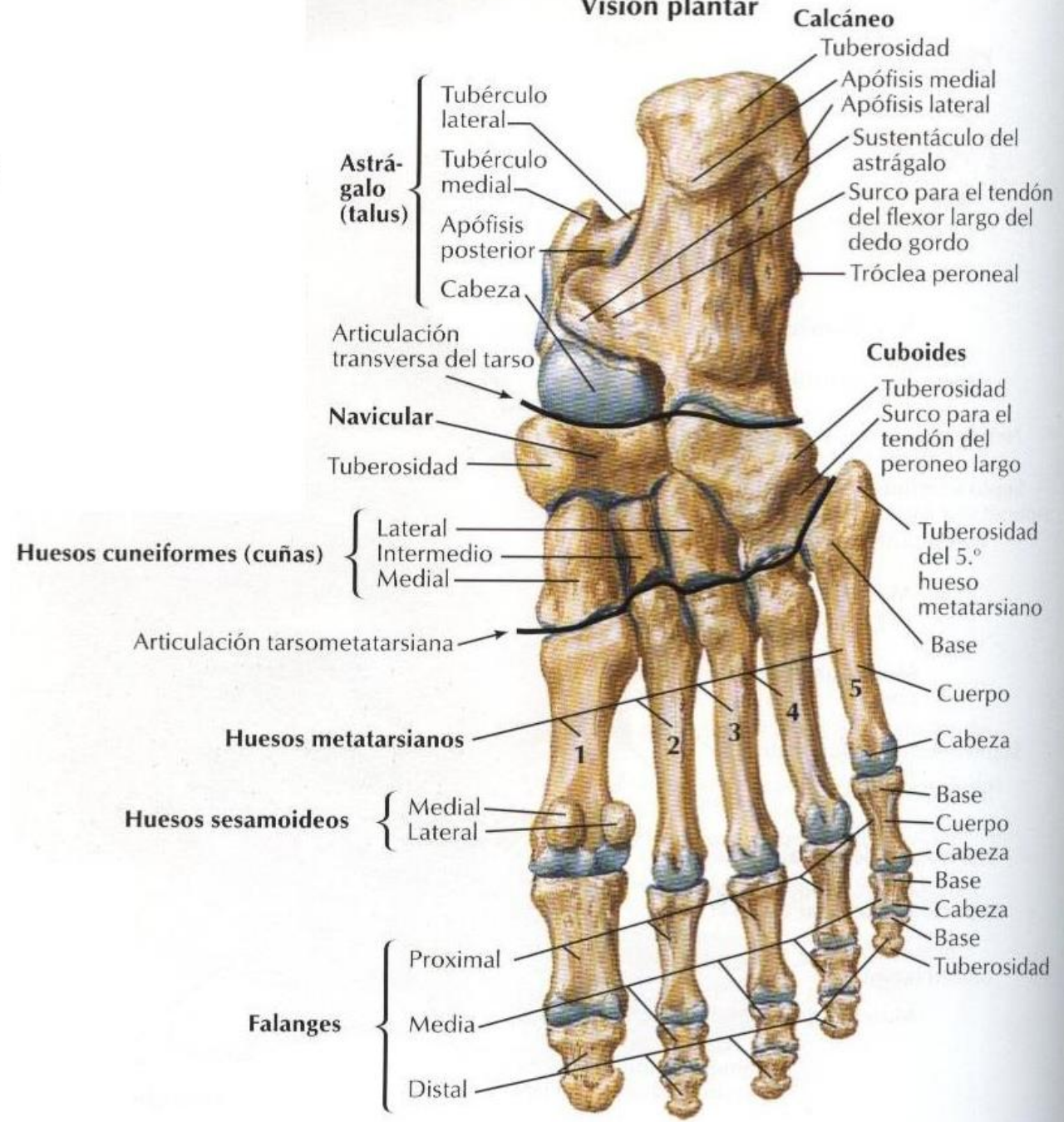
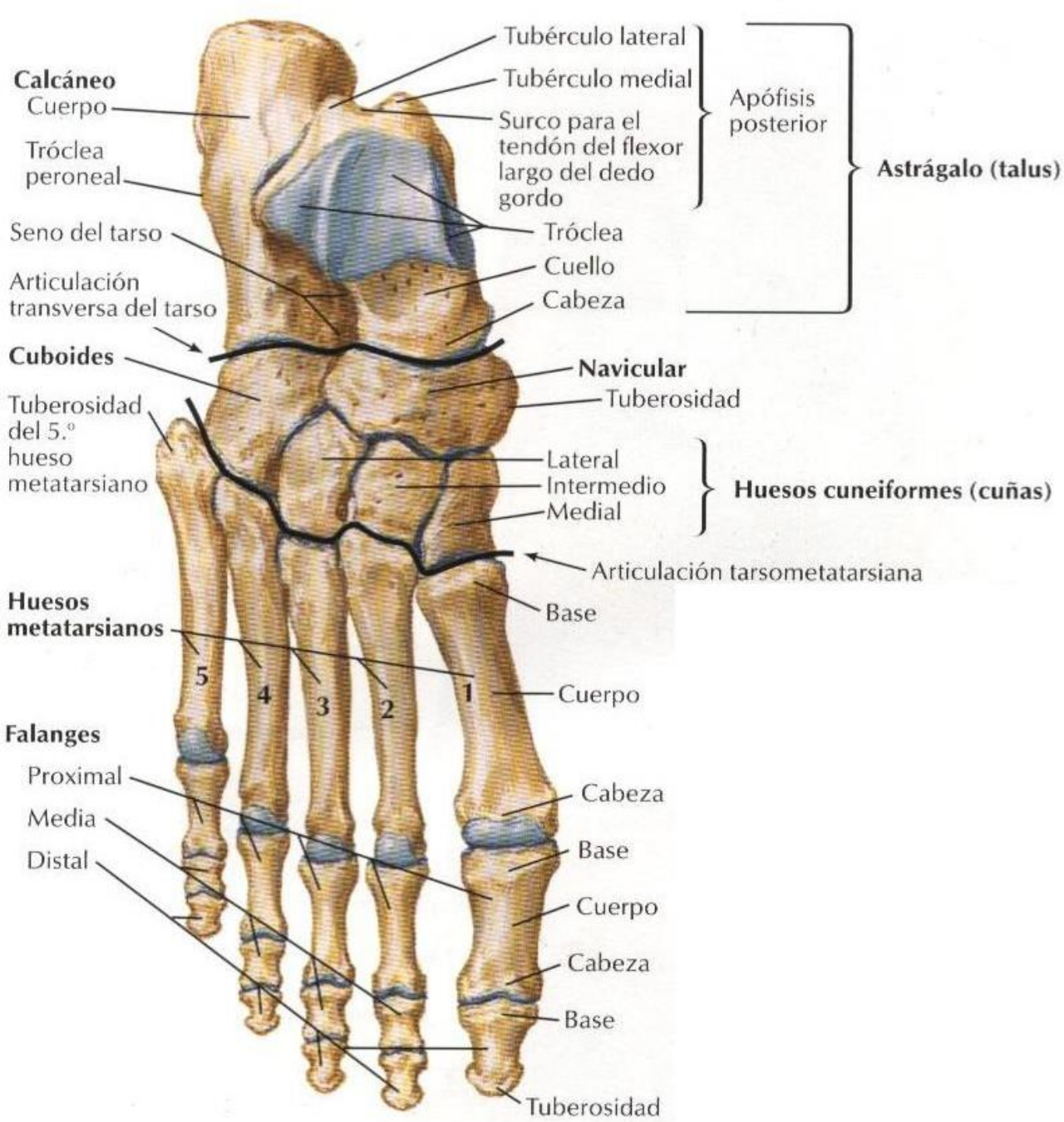


## Rodilla derecha: visión posterior

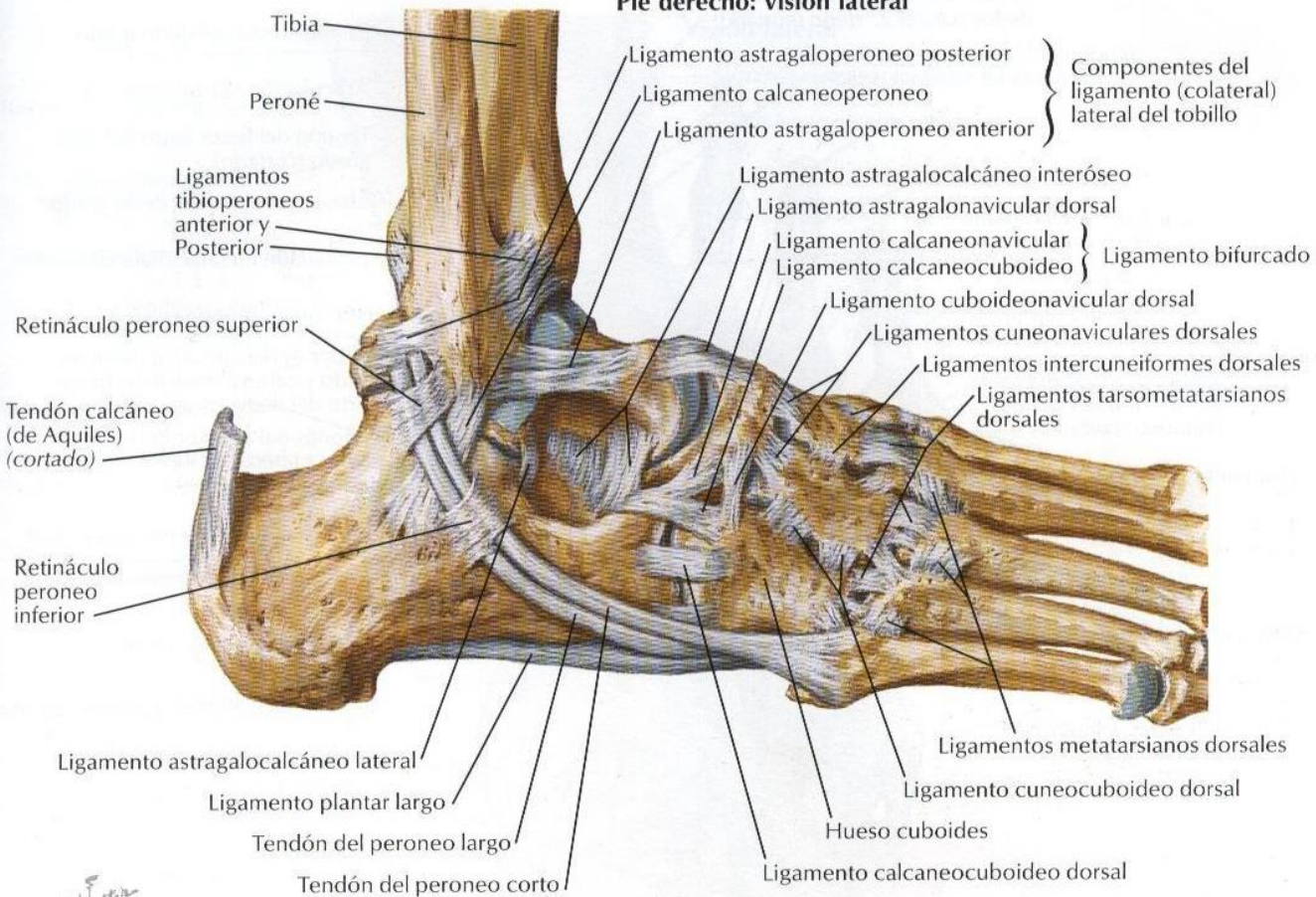




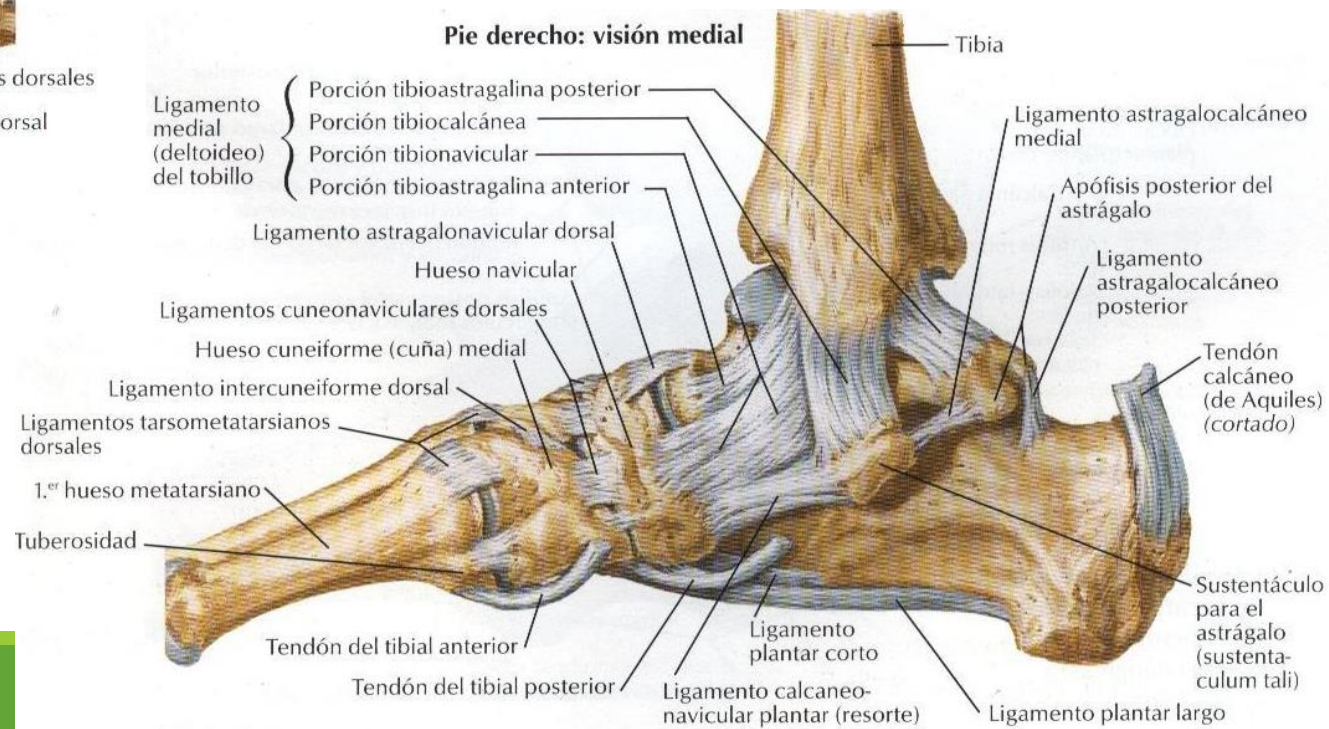




**Pie derecho: visión lateral**

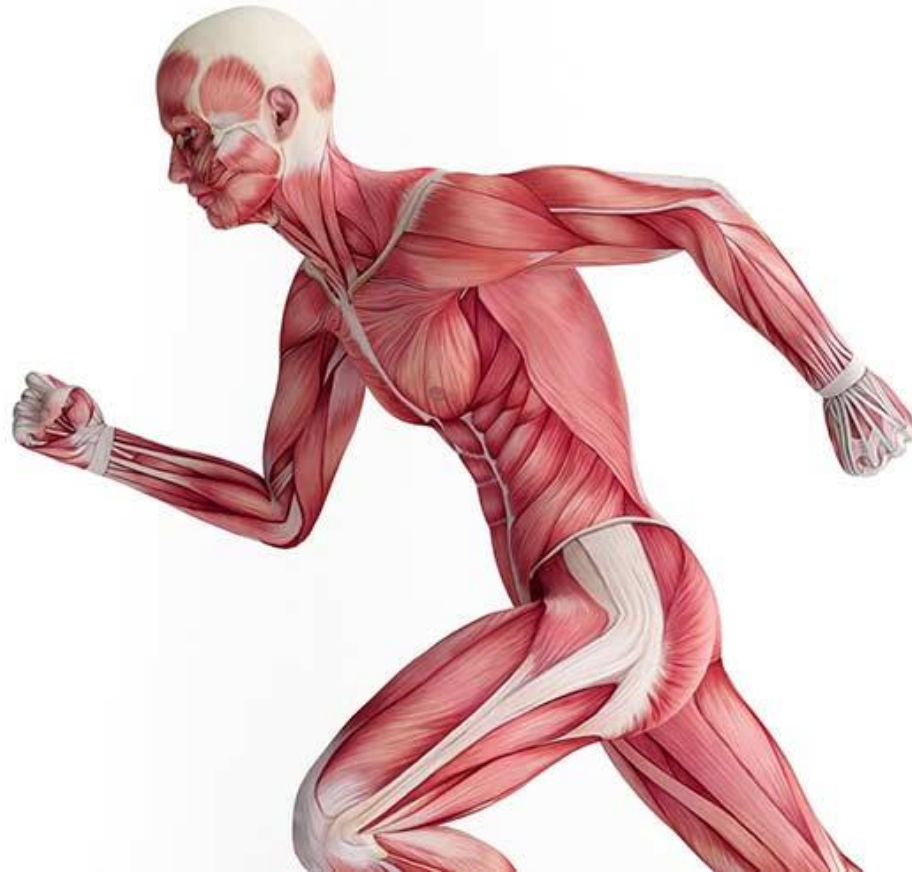

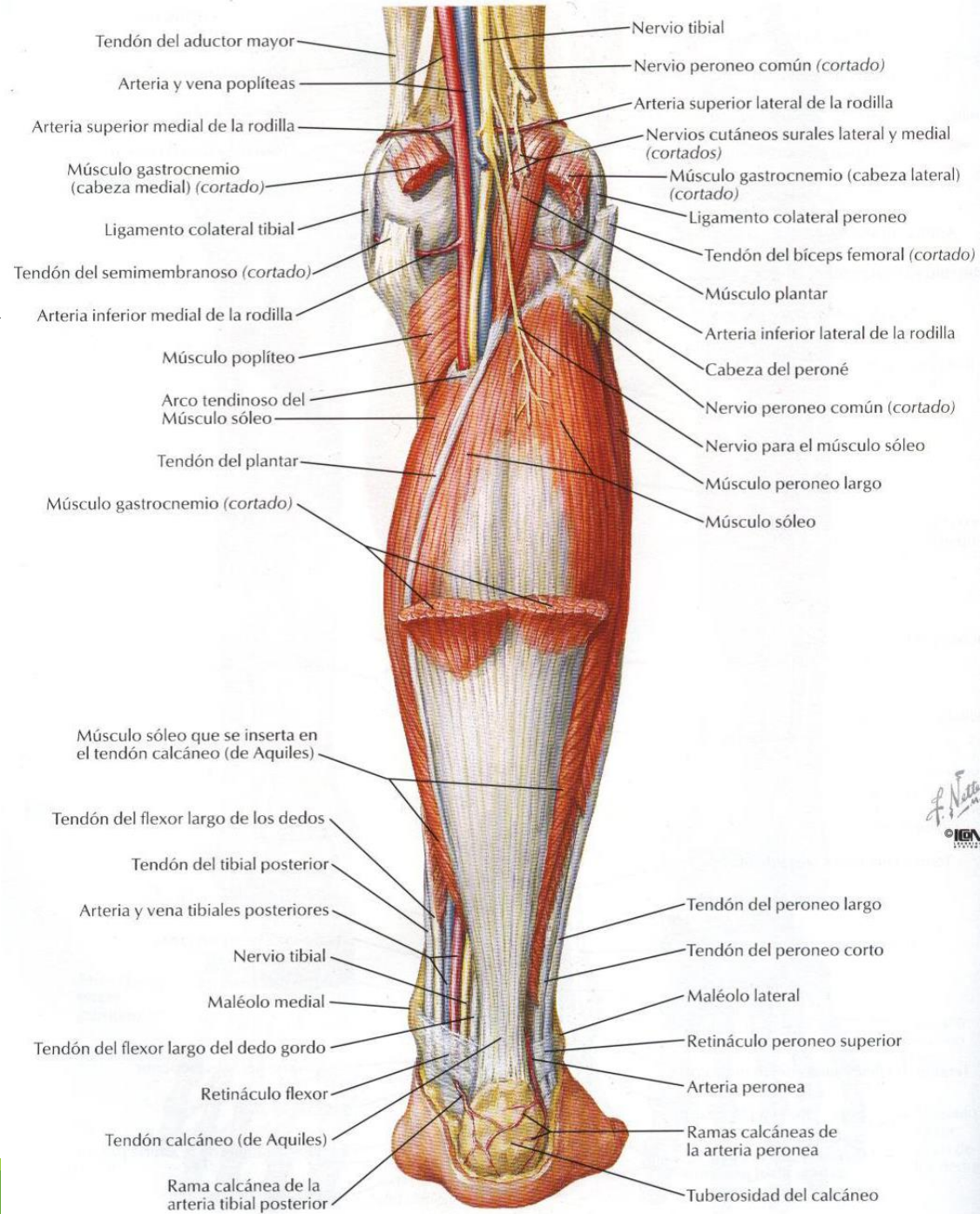
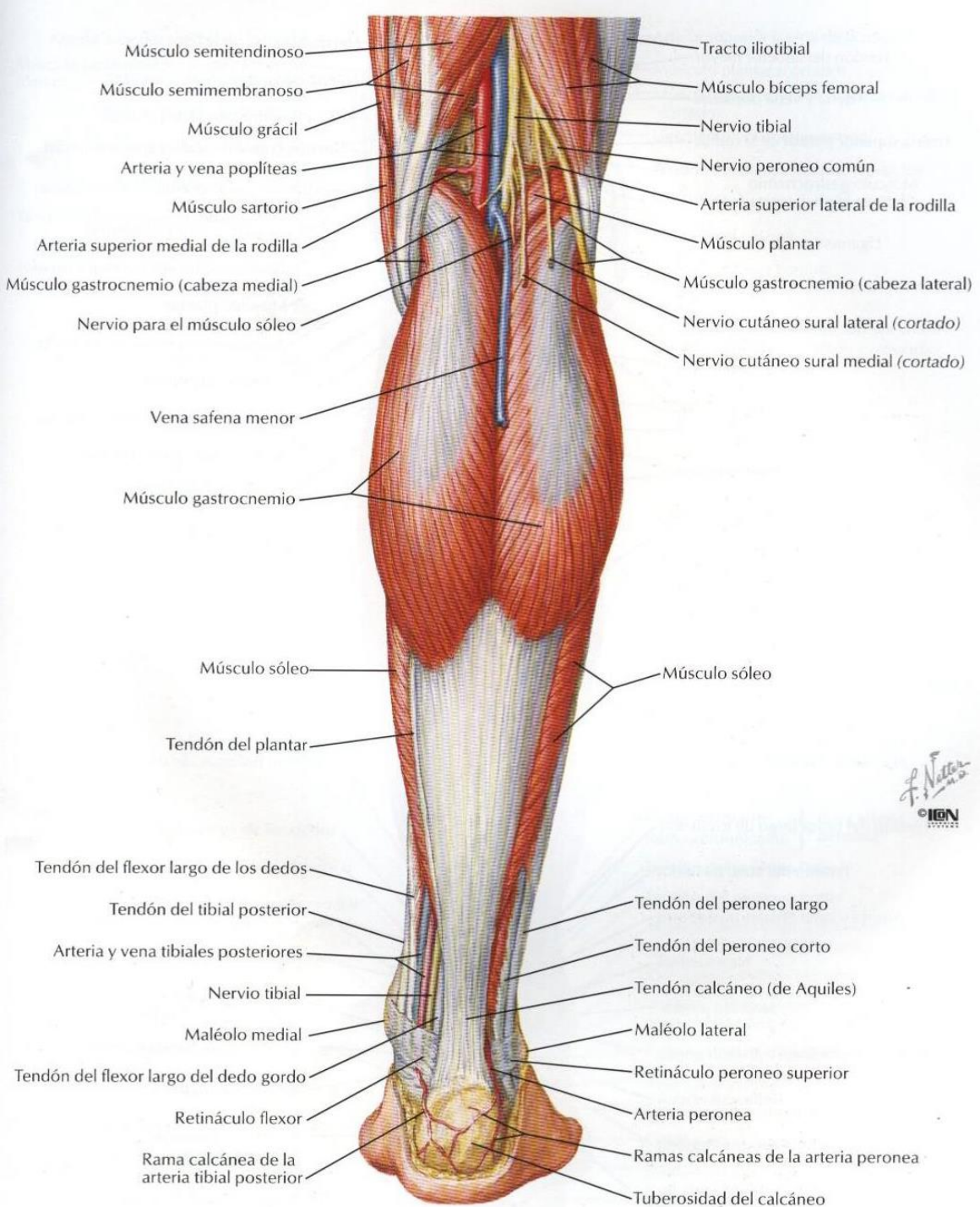
**Pie derecho: visión medial**

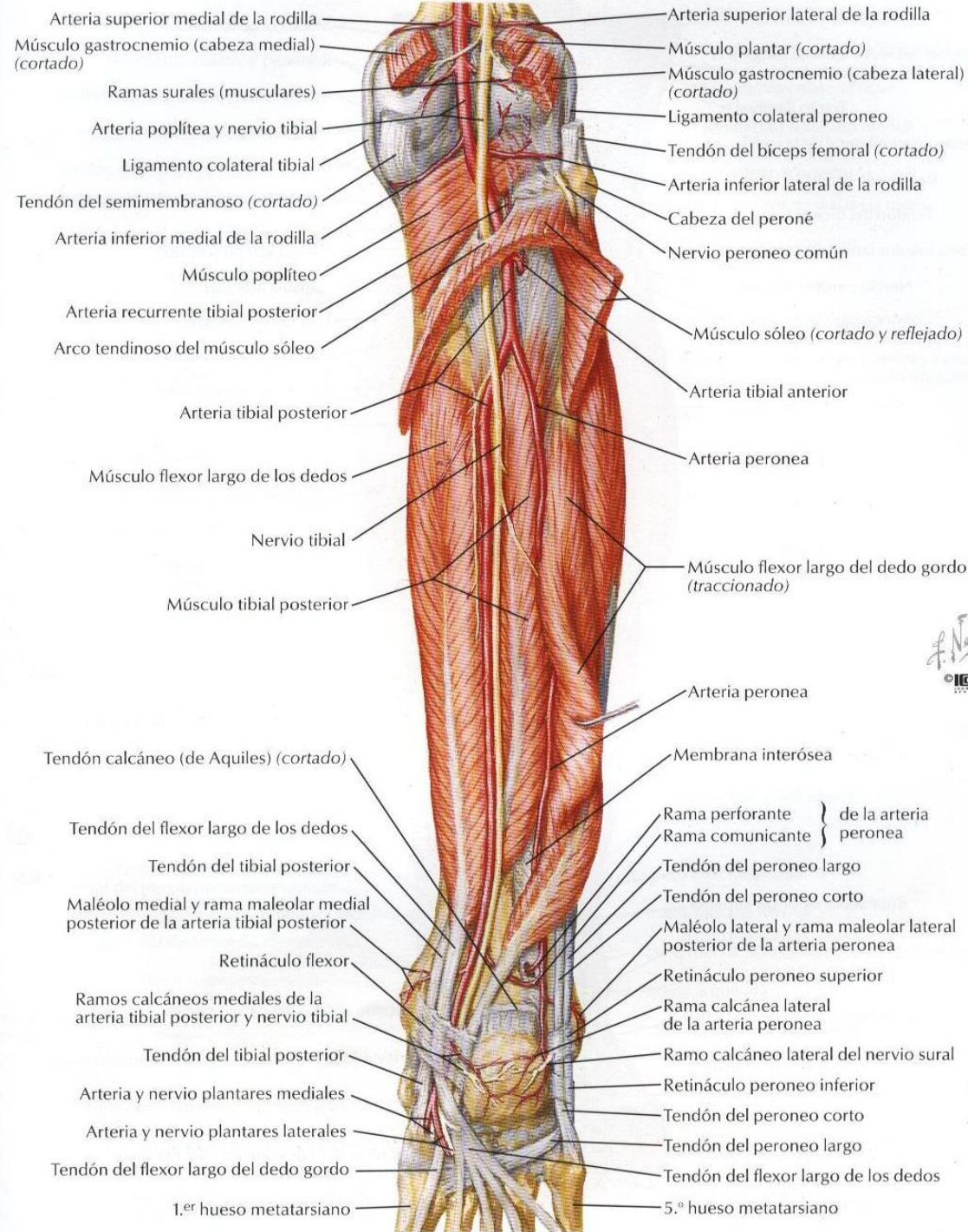


# Miología

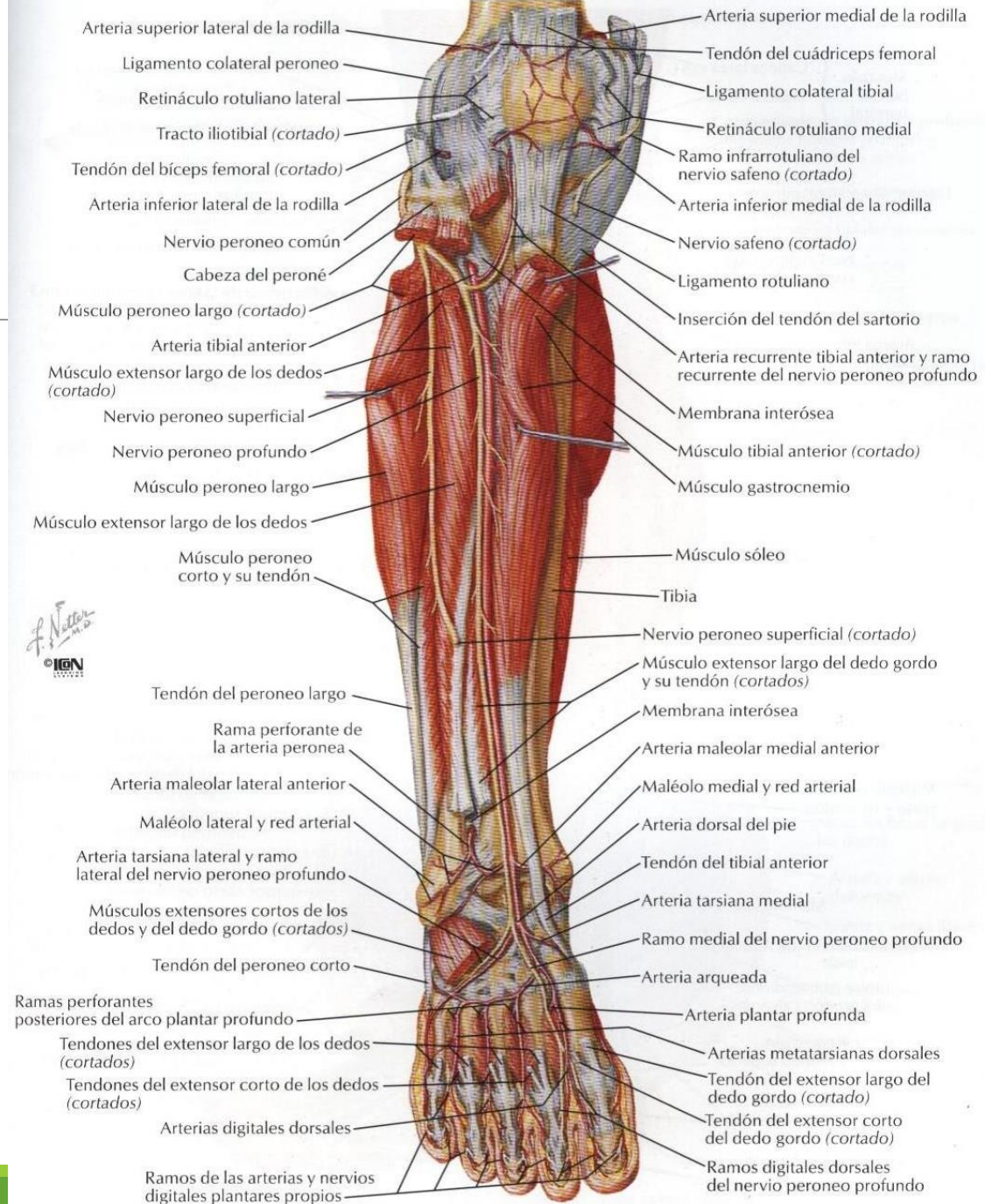
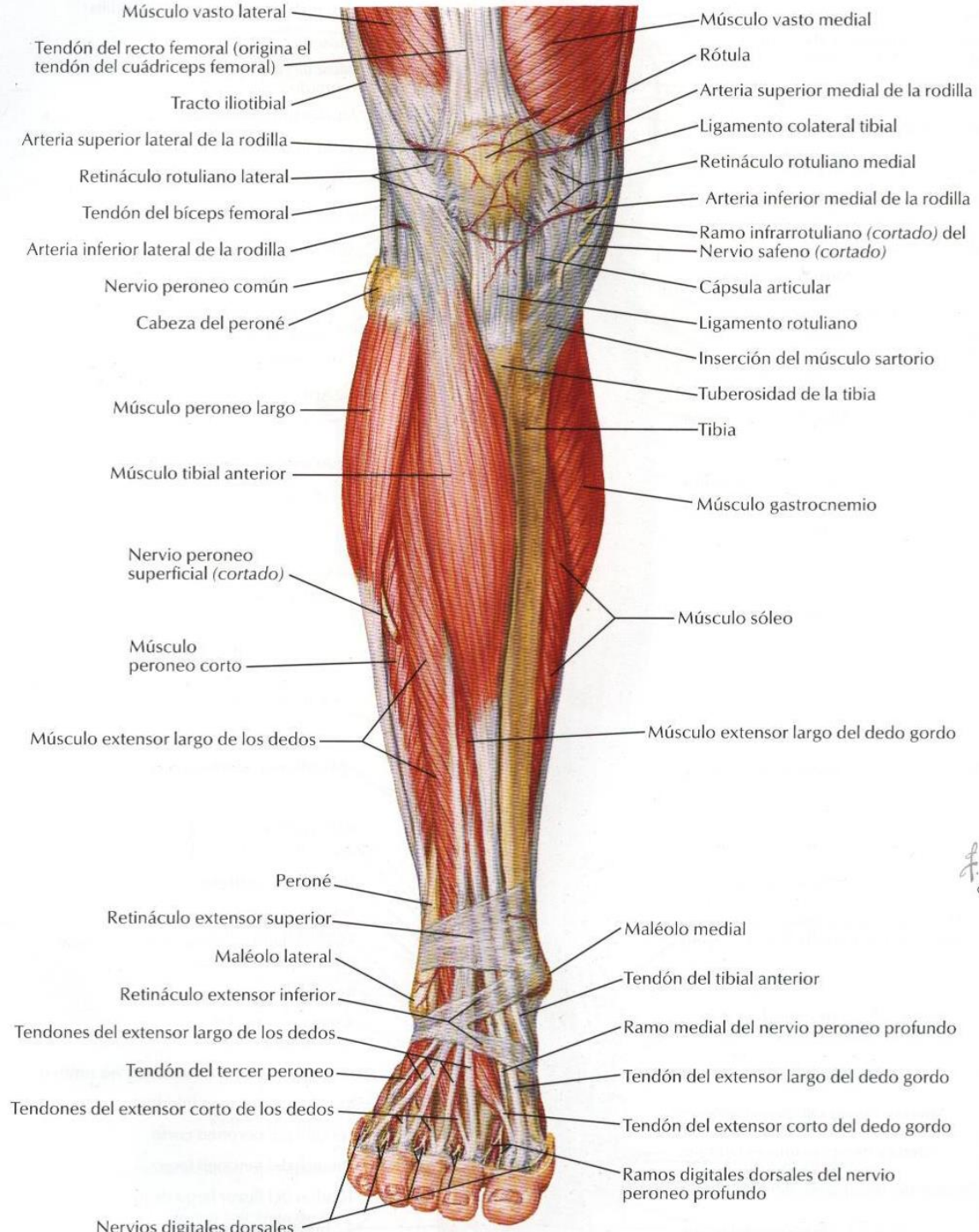
---

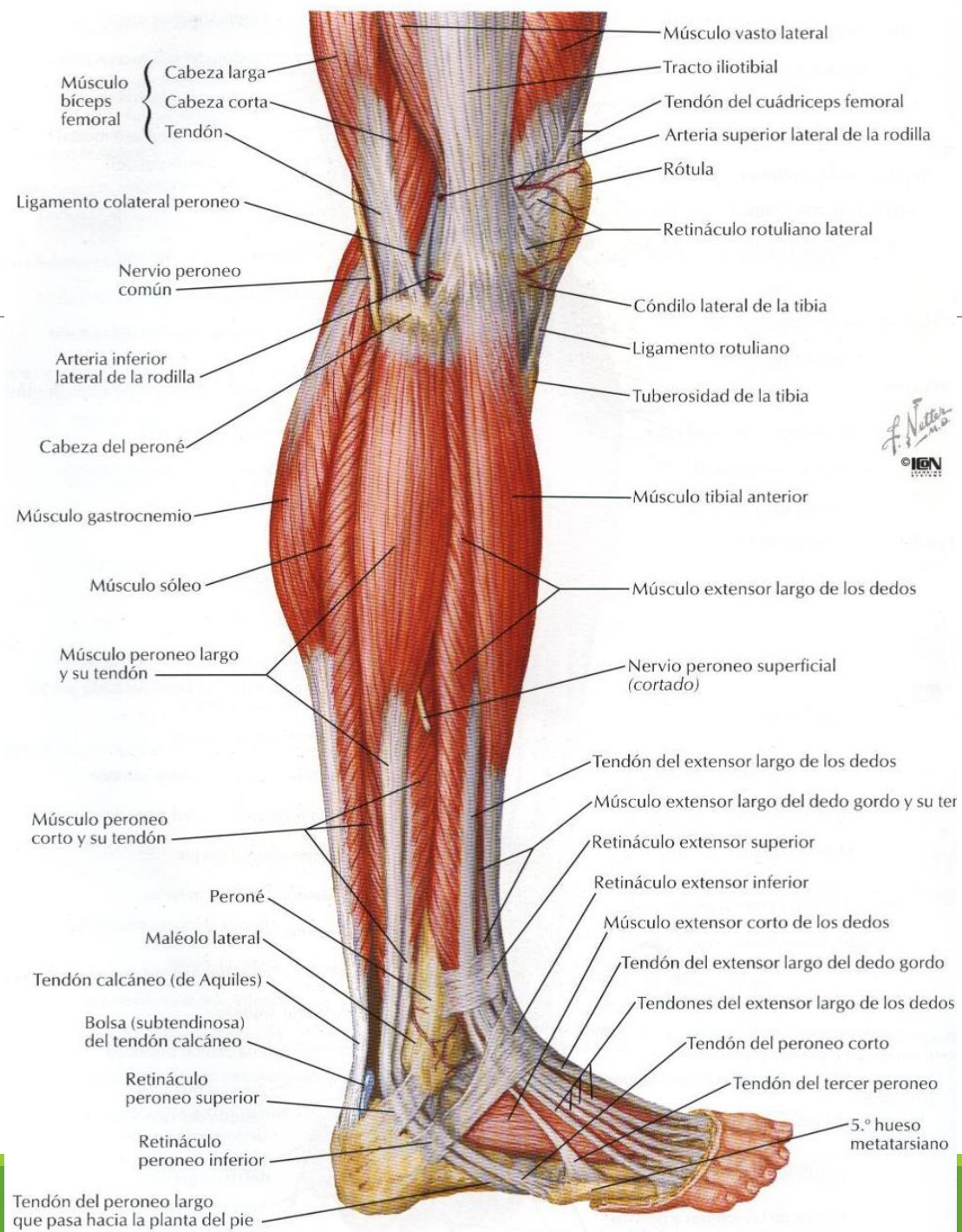






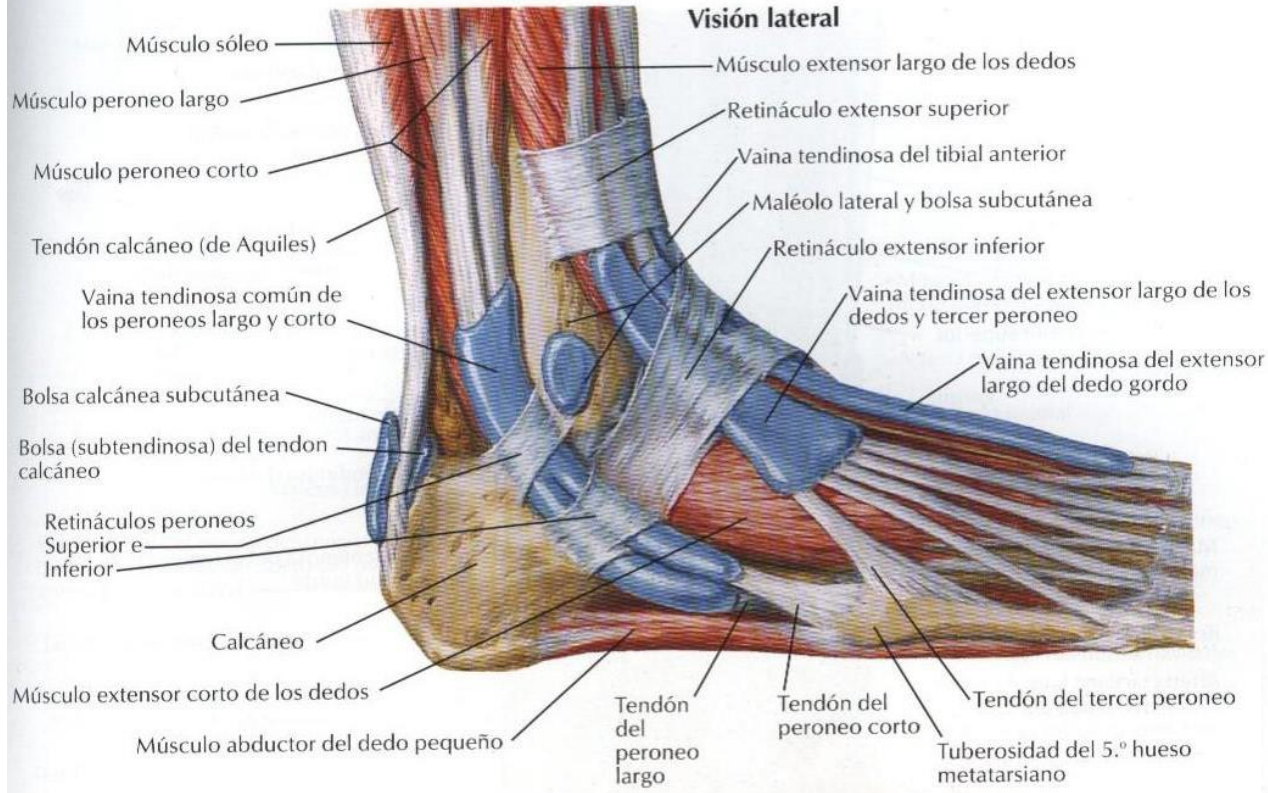
F. Netter  
© IEN



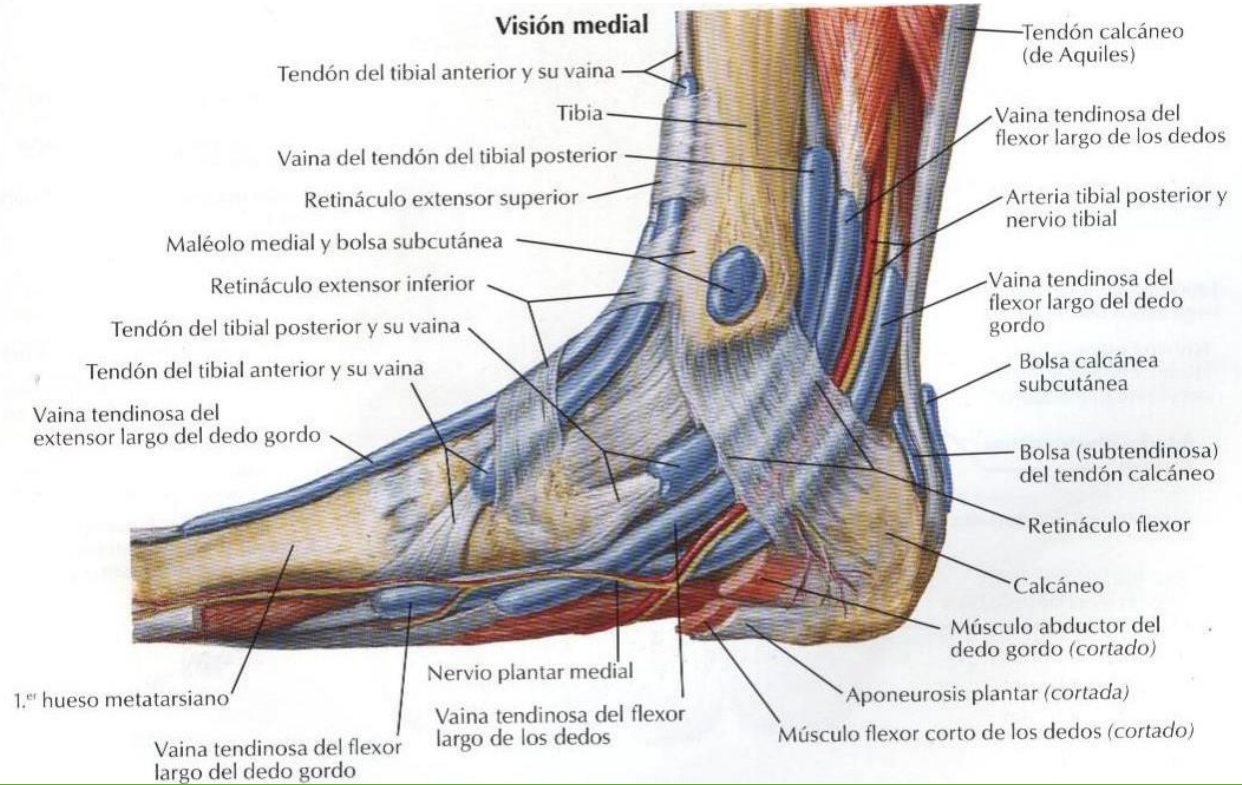


F. Natter  
 M.D.  
 IGEN

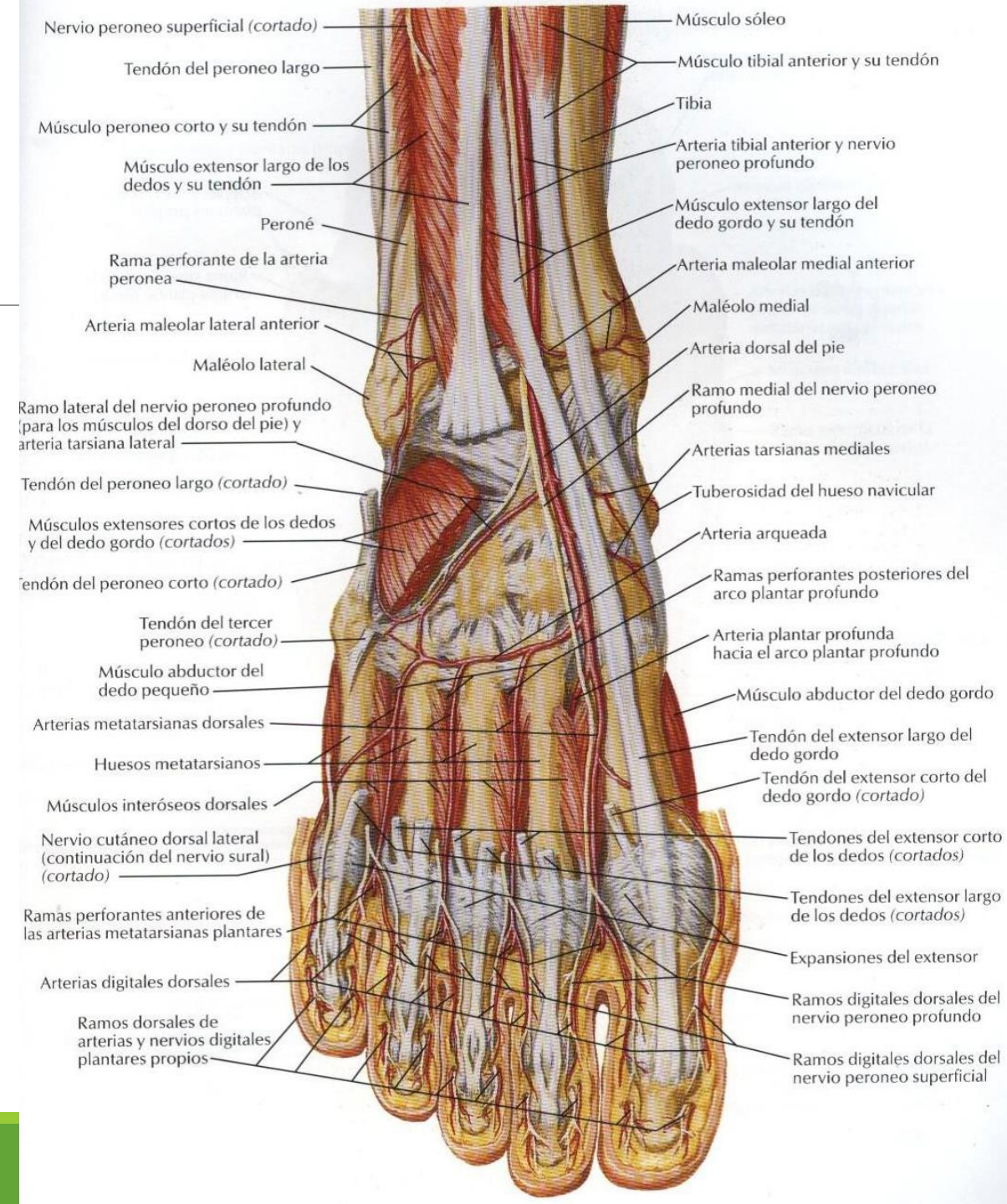
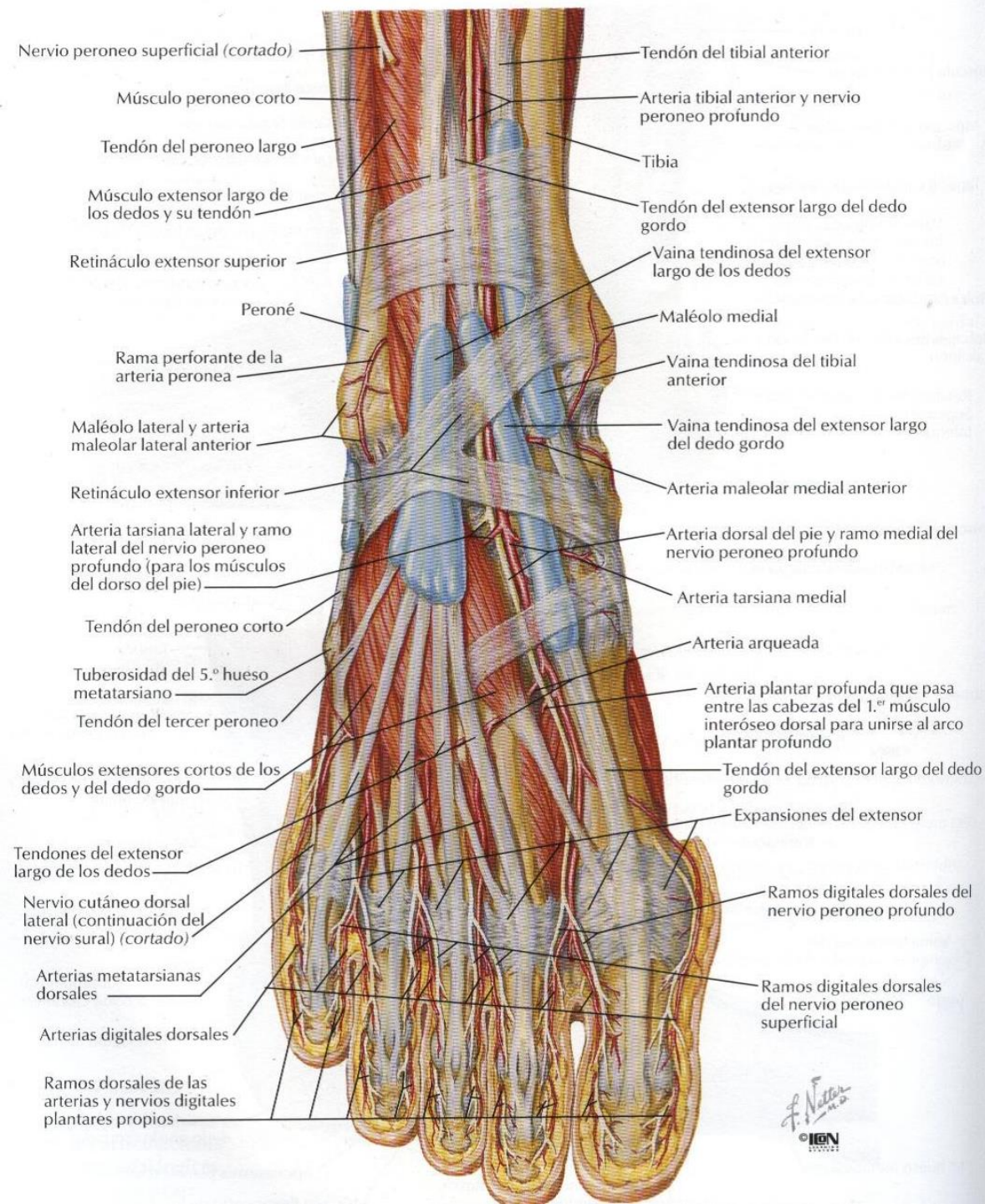
**Visión lateral**

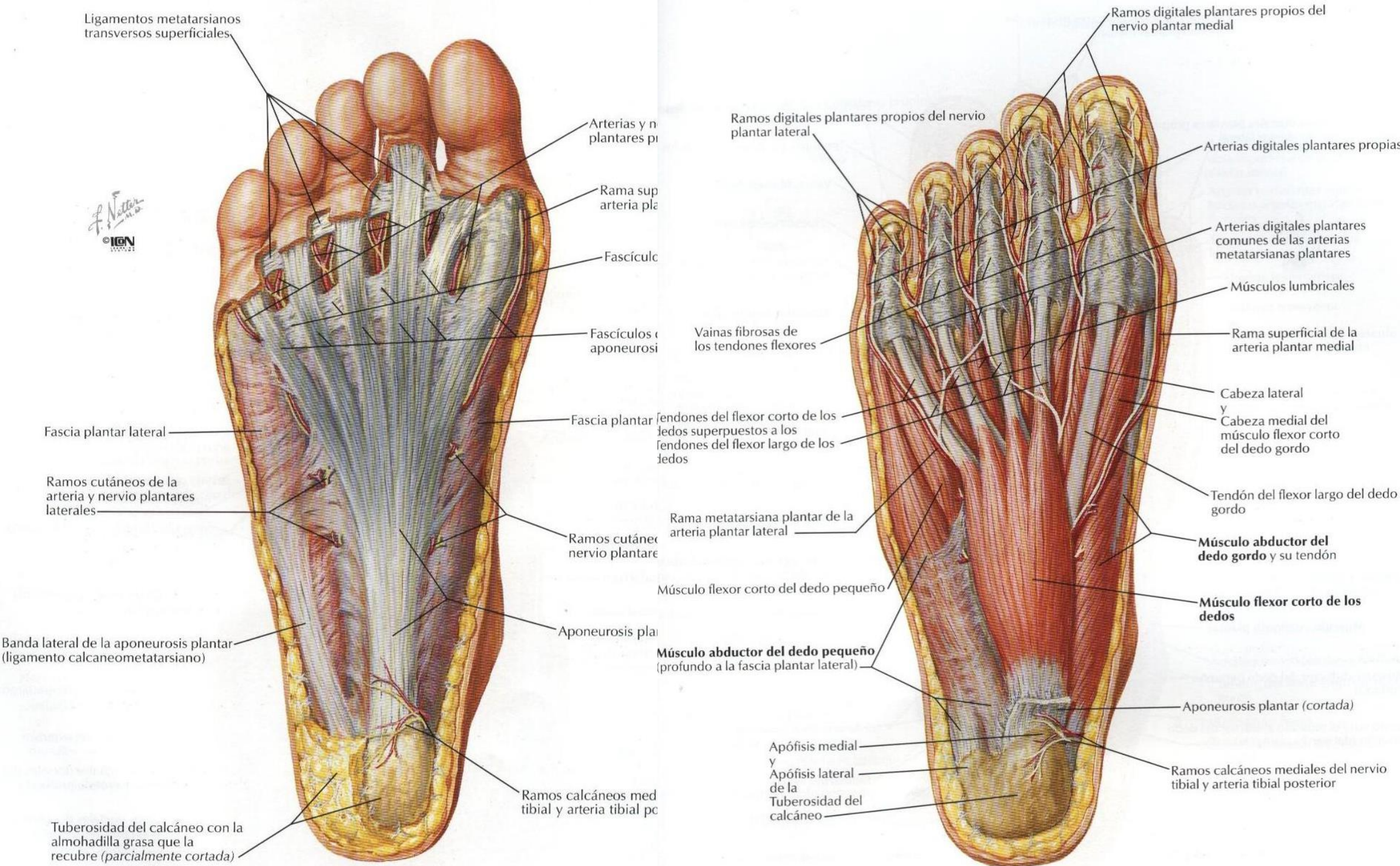


**Visión medial**









Ligamentos metatarsianos transversos superficiales

F. Netter  
© IGM

Arterias y n. plantares pr

Rama sup arteria pla

Fascículo

Fascículos o aponeurosi

Fascia plantar lateral

Ramos cutáneos de la arteria y nervio plantares laterales

Banda lateral de la aponeurosis plantar (ligamento calcaneometatarsiano)

Tuberosidad del calcáneo con la almohadilla grasa que la recubre (parcialmente cortada)

Fascia plantar

Ramos cutáneos nervio plantare

Ramos calcáneos med tibial y arteria tibial po

Aponeurosis pla

Ramos calcáneos med tibial y arteria tibial po

Ramos digitales plantares propios del nervio plantar lateral

Vainas fibrosas de los tendones flexores

Tendones del flexor corto de los dedos superpuestos a los tendones del flexor largo de los dedos

Rama metatarsiana plantar de la arteria plantar lateral

Músculo flexor corto del dedo pequeño

Músculo abductor del dedo pequeño (profundo a la fascia plantar lateral)

Apófisis medial y Apófisis lateral de la Tuberosidad del calcáneo

Ramos digitales plantares propios del nervio plantar medial

Arterias digitales plantares propias

Arterias digitales plantares comunes de las arterias metatarsianas plantares

Músculos lumbricales

Rama superficial de la arteria plantar medial

Cabeza lateral y Cabeza medial del músculo flexor corto del dedo gordo

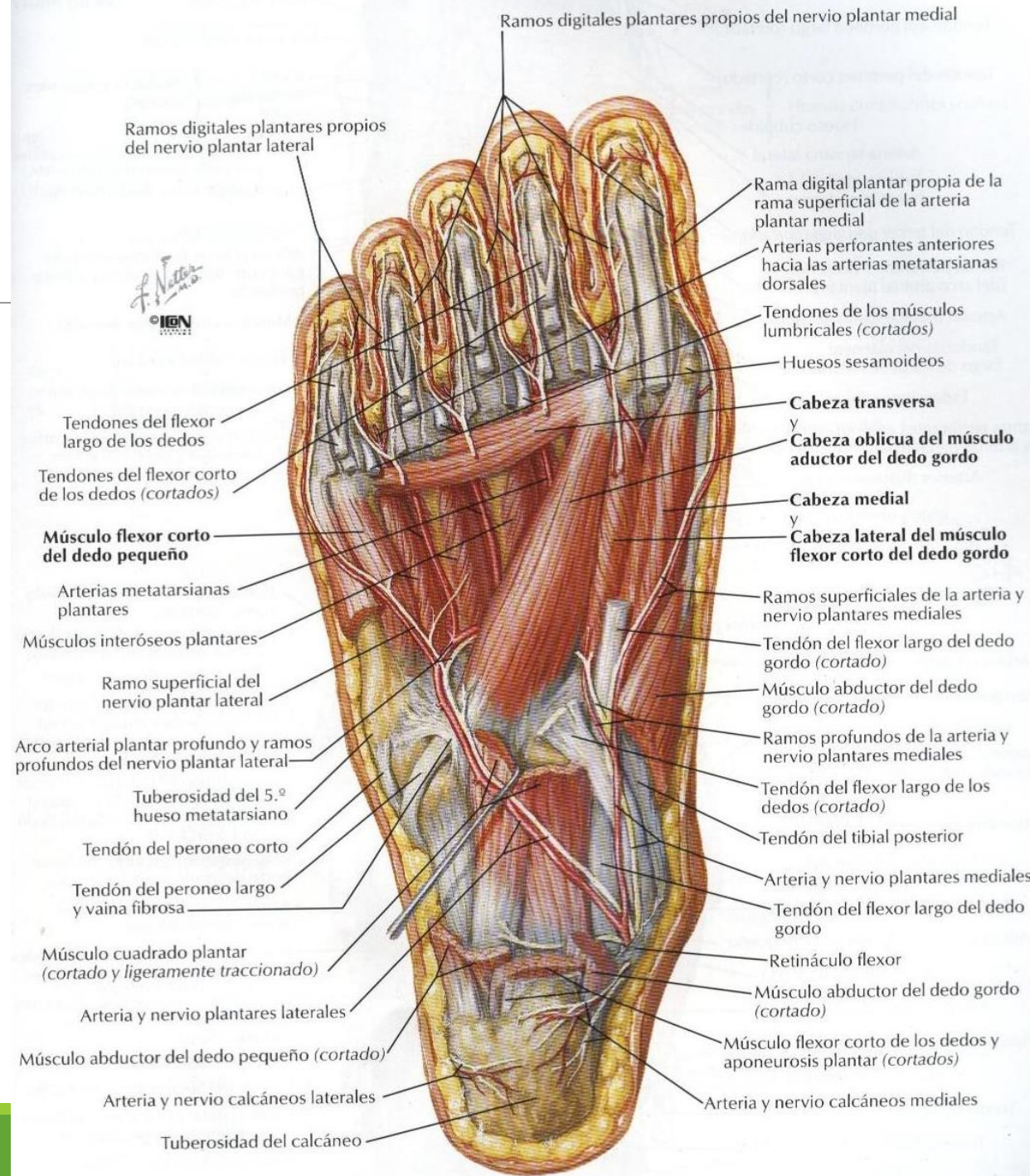
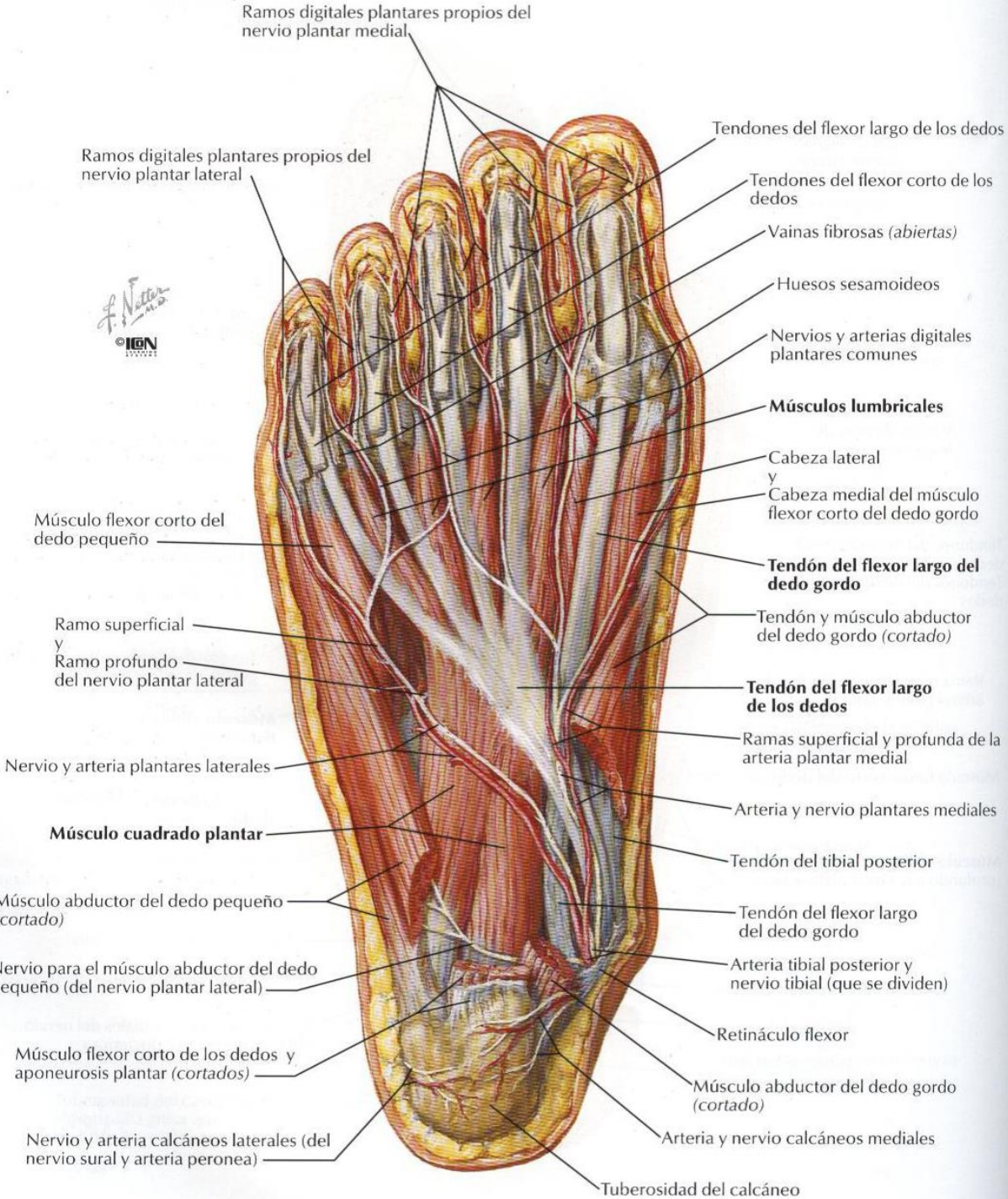
Tendón del flexor largo del dedo gordo

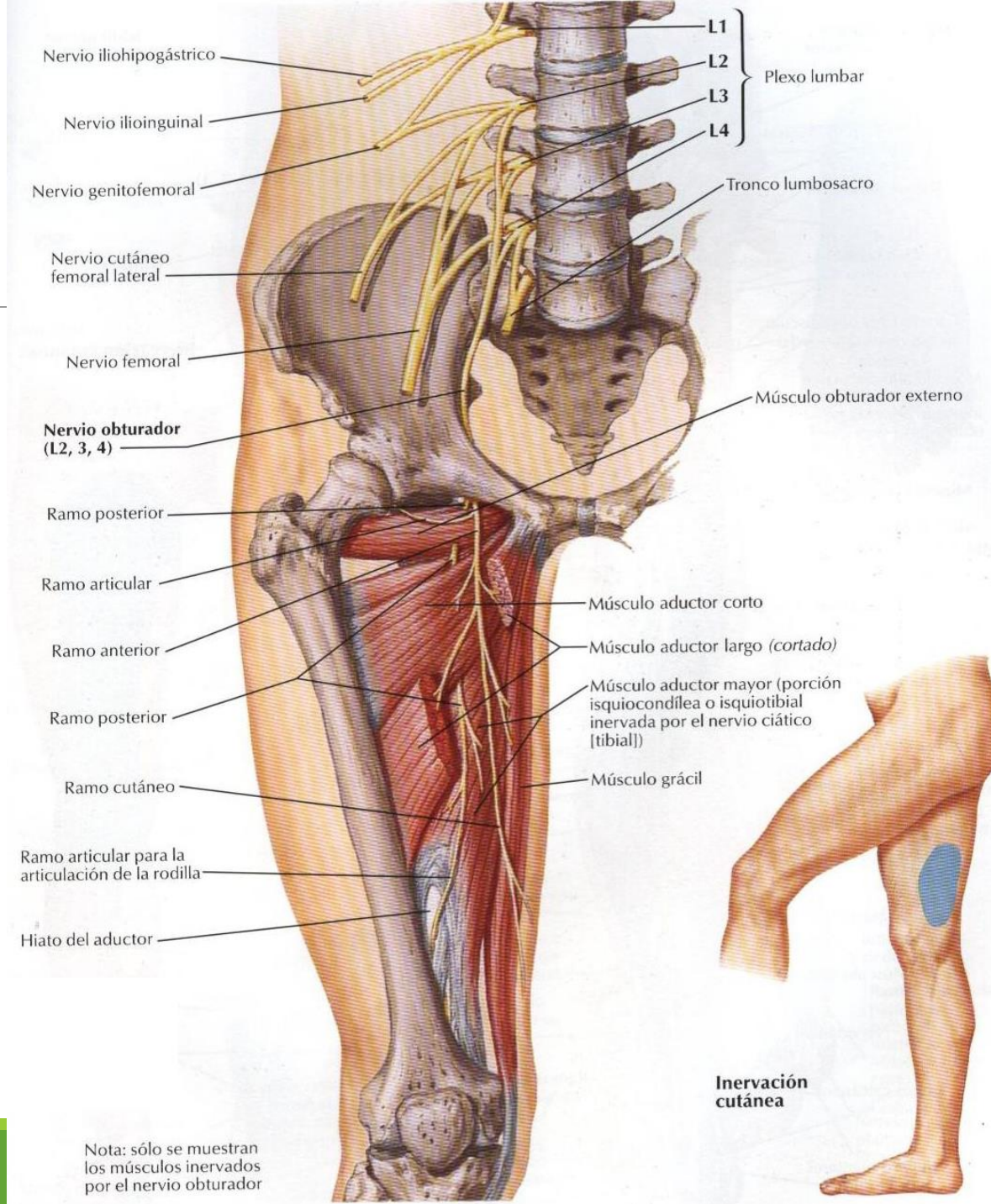
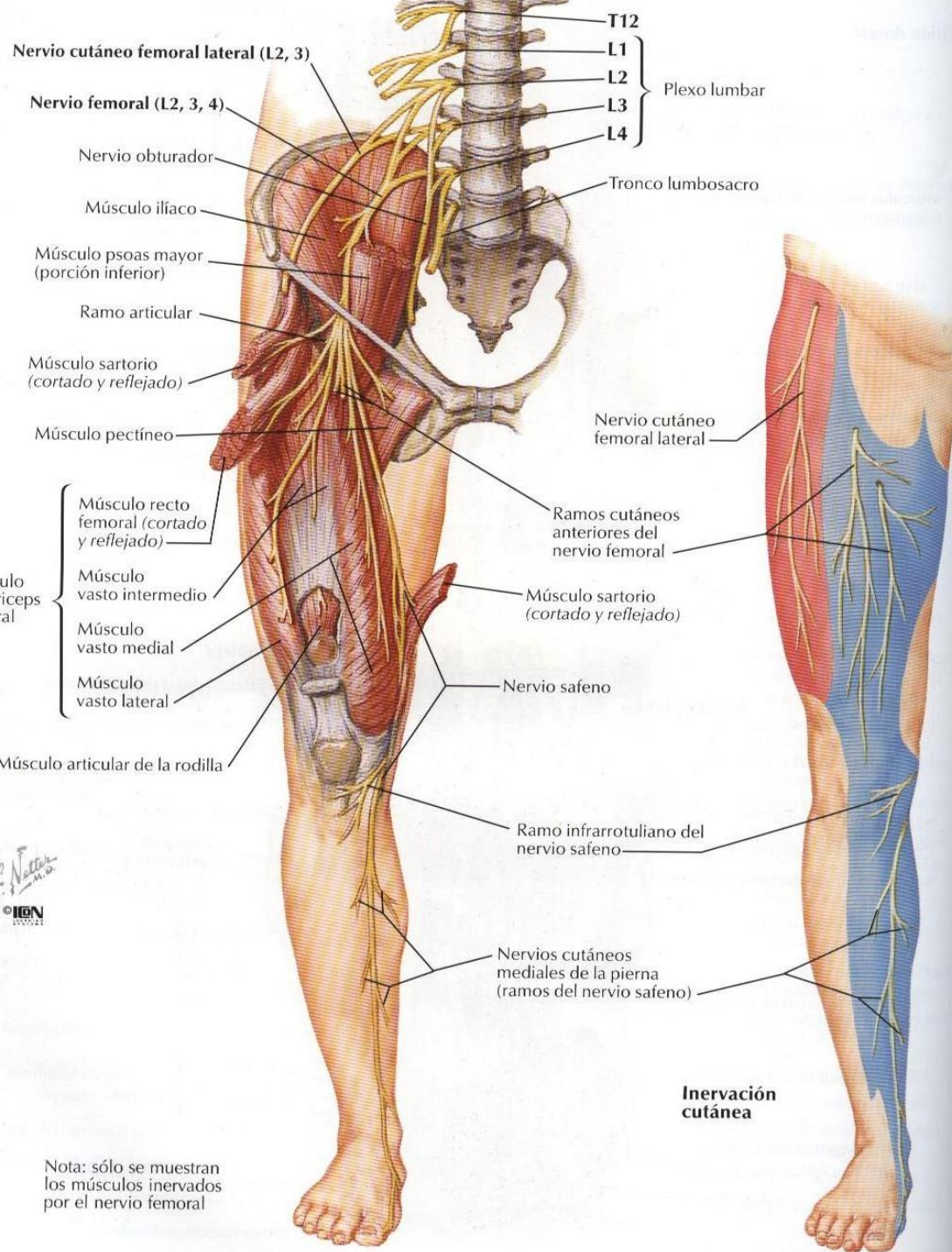
Músculo abductor del dedo gordo y su tendón

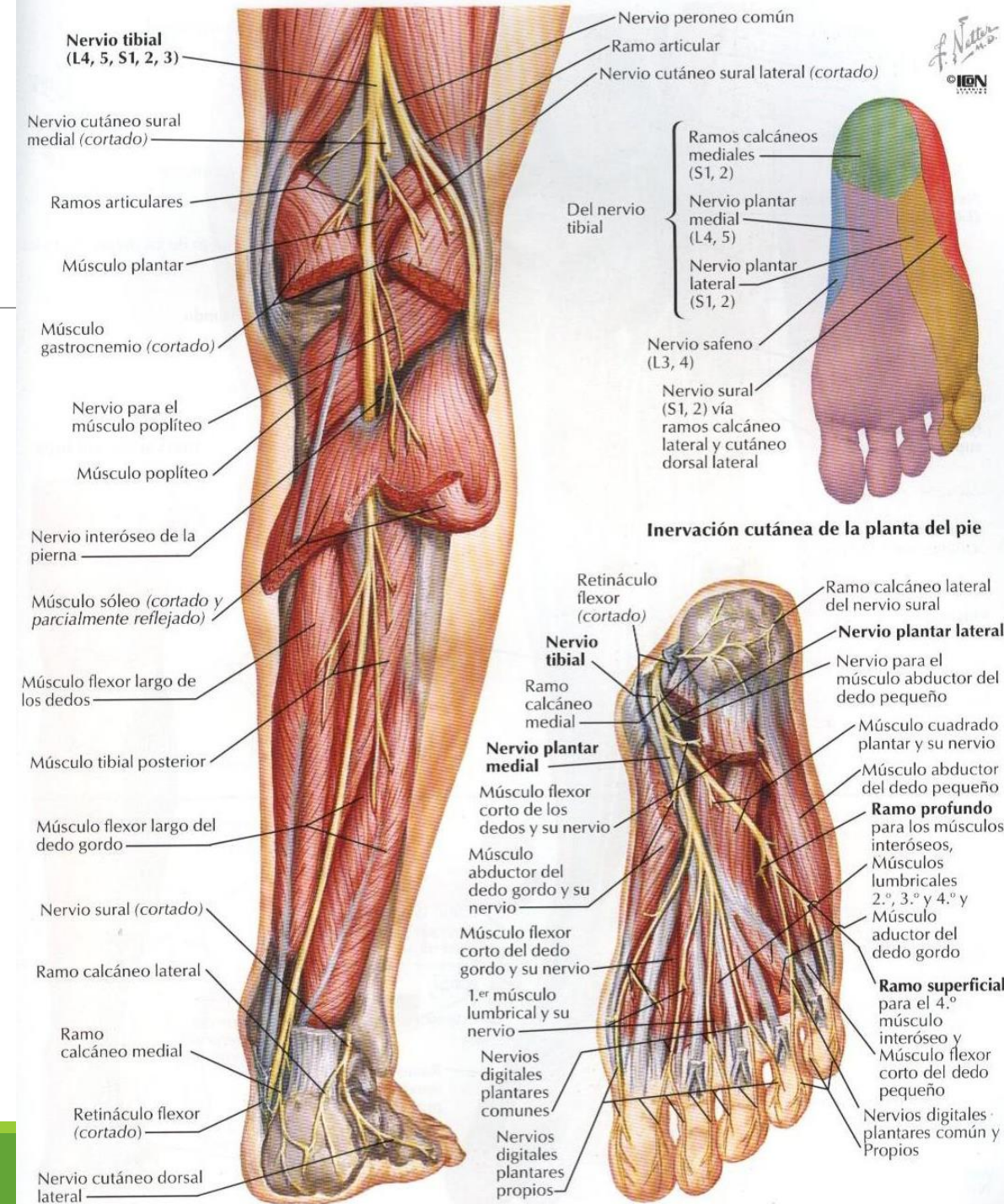
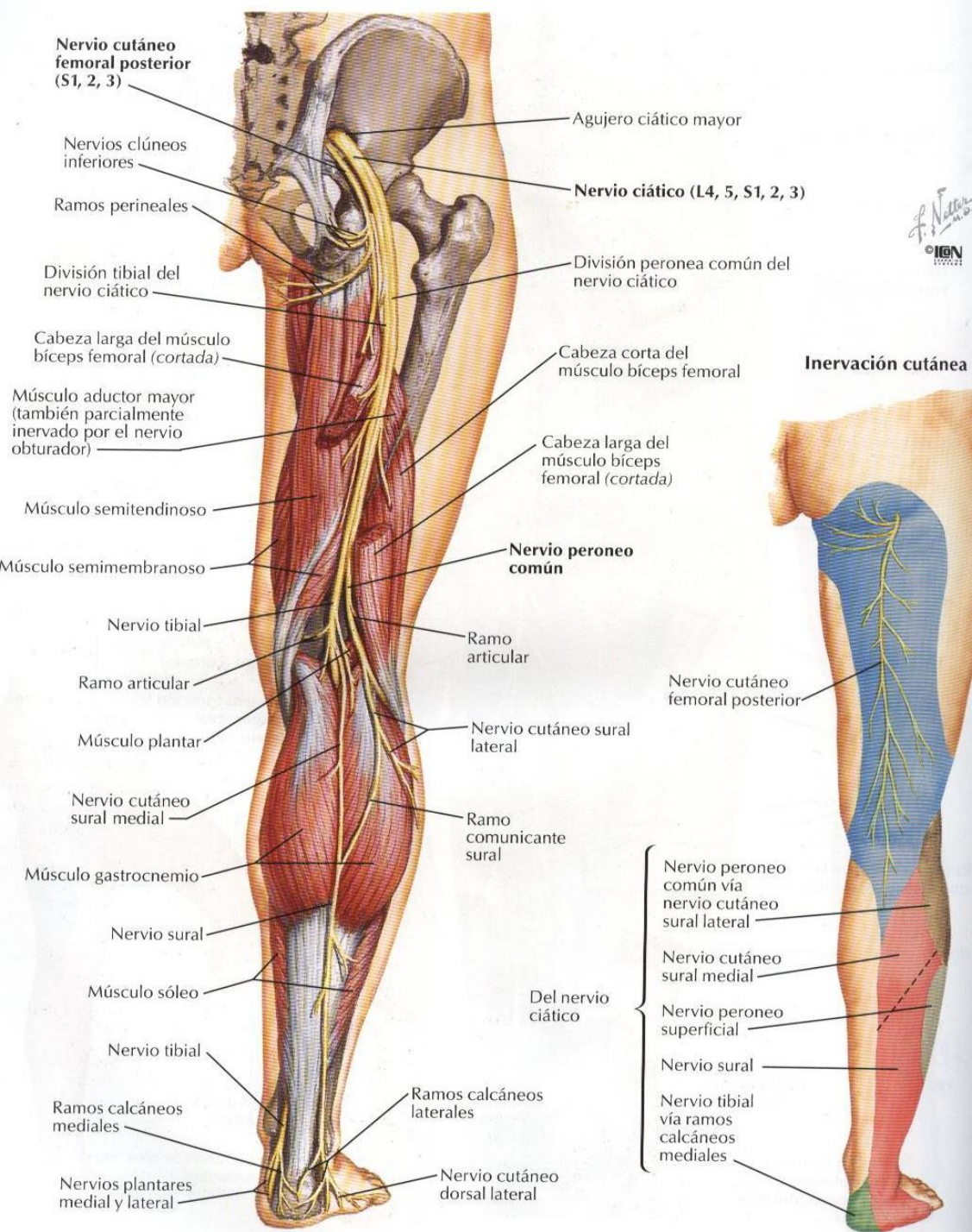
Músculo flexor corto de los dedos

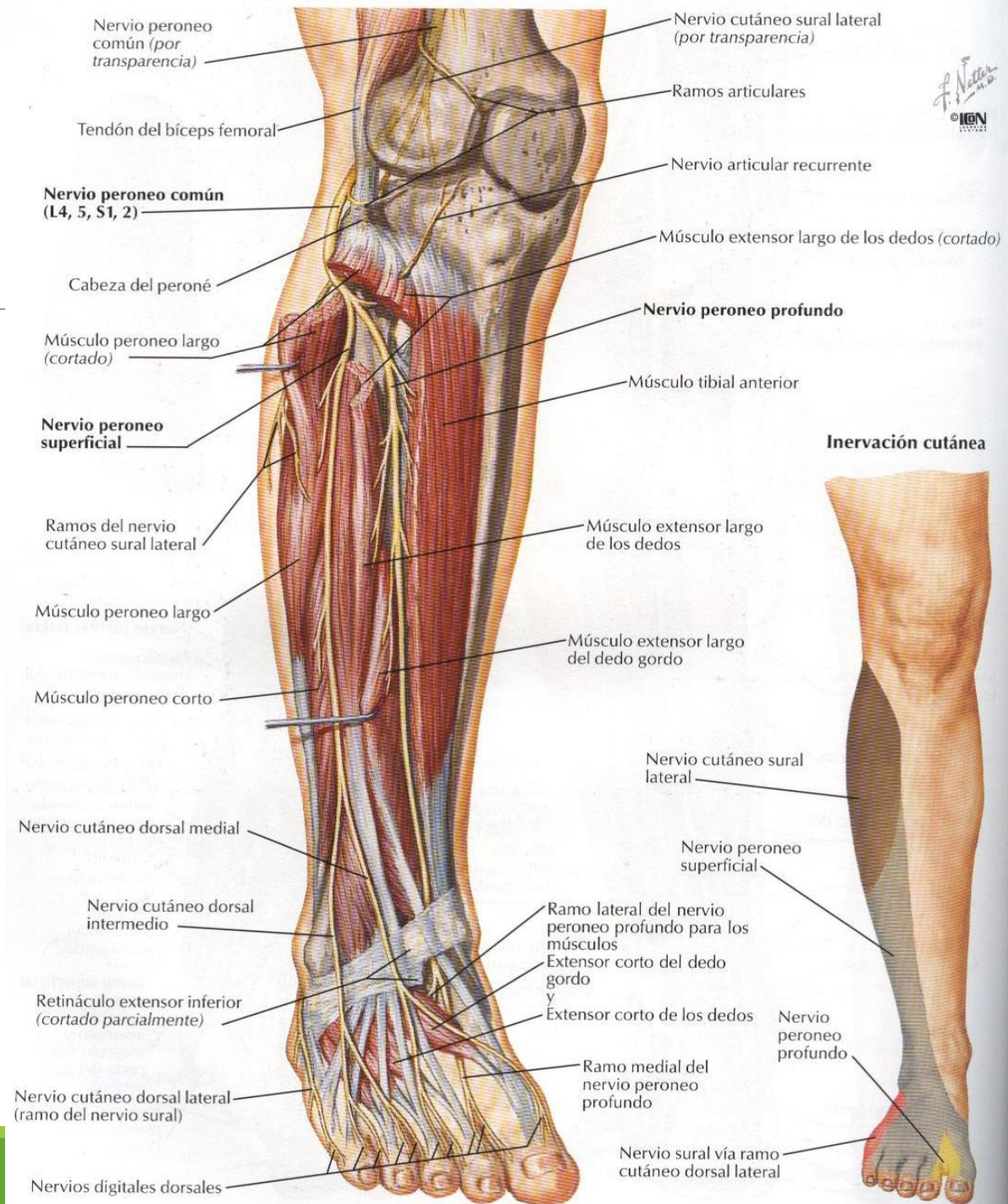
Aponeurosis plantar (cortada)

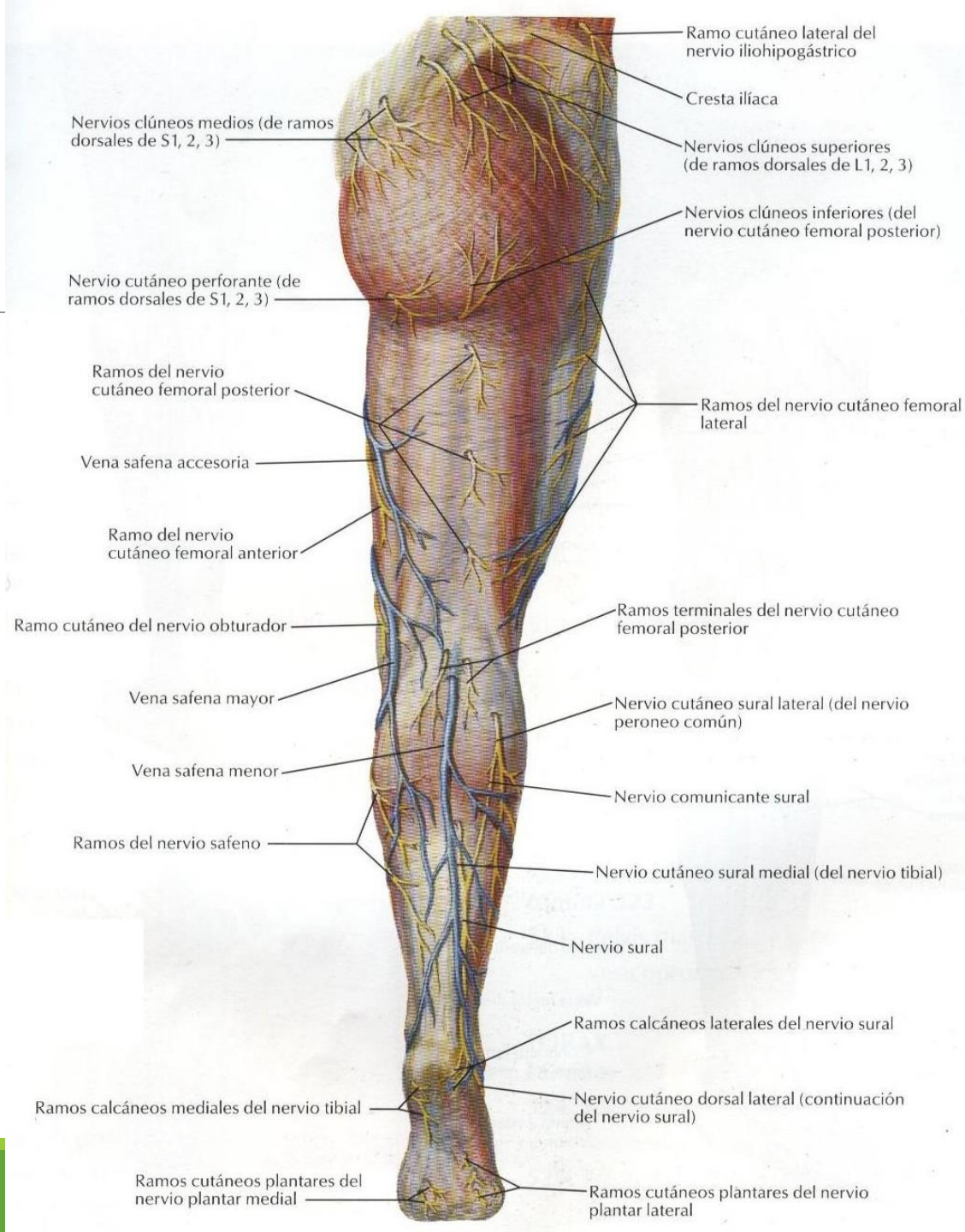
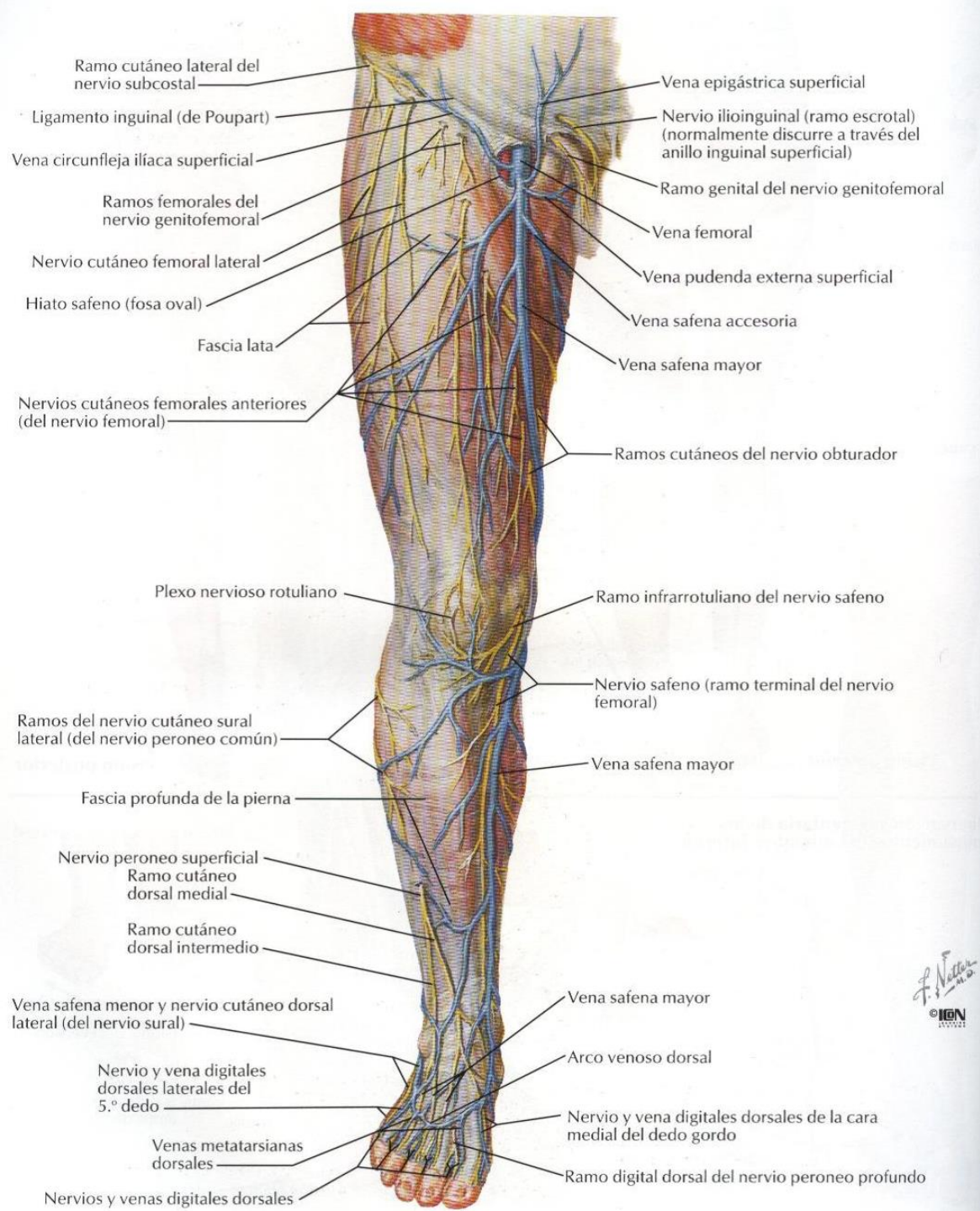
Ramos calcáneos mediales del nervio tibial y arteria tibial posterior



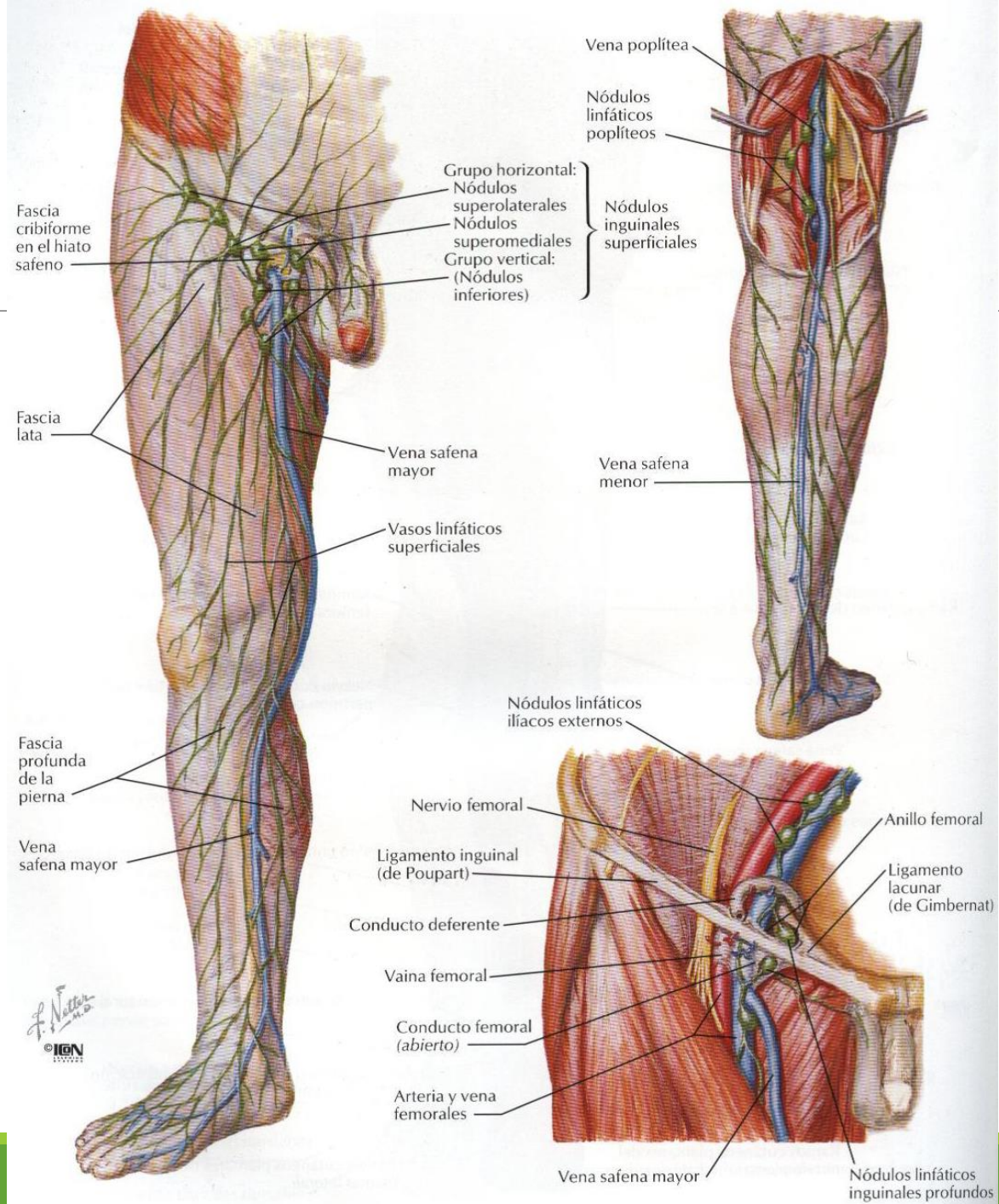








F. Netter  
© IGM



F. Netter  
 M.D.  
 © IGM